

# Use of corticosteroids for adult chronic pain interventions: sympathetic and peripheral nerve blocks, trigger point injections - guidelines from the American Society of Regional Anesthesia and Pain Medicine, the American Academy of Pain Medicine, the American Society of Interventional Pain Physicians, the International Pain and Spine Intervention Society, and the North American Spine Society

Honorio T Benzon <sup>1</sup>, Dalia Elmofty <sup>2</sup>, Hariharan Shankar <sup>3</sup>, Maunak Rana,<sup>2</sup> Andrea L Chadwick <sup>4</sup>, Shalini Shah <sup>5</sup>, Dmitri Souza,<sup>6</sup> Ameet S Nagpal <sup>7</sup>, Salahadin Abdi <sup>8</sup>, Christian Rafla <sup>9</sup>, Alaa Abd-Elseyed,<sup>10</sup> Tina L Doshi <sup>11</sup>, Maxim S Eckmann,<sup>12</sup> Thanh D Hoang <sup>13</sup>, Christine Hunt <sup>14</sup>, Carlos A Pino <sup>15</sup>, Jessica Rivera,<sup>16</sup> Byron J Schneider <sup>17</sup>, Alison Stout <sup>18</sup>, Angela Stengel <sup>19</sup>, Maged Mina,<sup>20</sup> John D FitzGerald <sup>21</sup>, Joshua A Hirsch,<sup>22</sup> Ajay D Wasan <sup>23</sup>, Laxmaiah Manchikanti,<sup>24</sup> David Anthony Provenzano <sup>25</sup>, Samer Narouze <sup>26</sup>, Steven P Cohen <sup>1,27</sup>, Timothy P Maus,<sup>28</sup> Ariana M Nelson <sup>29,30</sup>, Harsha Shanthanna <sup>31</sup>

► Additional supplemental material is published online only. To view, please visit the journal online (<https://doi.org/10.1136/rapm-2024-105593>).

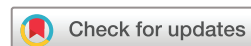For numbered affiliations see end of article.

## Correspondence to

Dr Honorio T Benzon, Anesthesiology, Feinberg School of Medicine, Chicago, IL 60611, USA; [hobenzon@nm.org](mailto:hobenzon@nm.org)

AMN and HS are joint senior authors.

Received 23 April 2024  
Accepted 14 June 2024



© American Society of Regional Anesthesia & Pain Medicine 2024. No commercial re-use. See rights and permissions. Published by BMJ.

**To cite:** Benzon HT, Elmofty D, Shankar H, et al. *Reg Anesth Pain Med* Epub ahead of print: [please include Day Month Year]. doi:10.1136/rapm-2024-105593

## ABSTRACT

**Background** There is potential for adverse events from corticosteroid injections, including increase in blood glucose, decrease in bone mineral density and suppression of the hypothalamic–pituitary axis. Published studies note that doses lower than those commonly injected provide similar benefit.

**Methods** Development of the practice guideline was approved by the Board of Directors of American Society of Regional Anesthesia and Pain Medicine with several other societies agreeing to participate. The scope of guidelines was agreed on to include safety of the injection technique (landmark-guided, ultrasound or radiology-aided injections); effect of the addition of the corticosteroid on the efficacy of the injectate (local anesthetic or saline); and adverse events related to the injection. Based on preliminary discussions, it was decided to structure the topics into three separate guidelines as follows: (1) sympathetic, peripheral nerve blocks and trigger point injections; (2) joints; and (3) neuraxial, facet, sacroiliac joints and related topics (vaccine and anticoagulants). Experts were assigned topics to perform a comprehensive review of the literature and to draft statements and recommendations, which were refined and voted for consensus (≥75% agreement) using a modified Delphi process. The United States Preventive Services Task Force grading of evidence and strength of recommendation was followed.

## KEY MESSAGES

- ⇒ The addition of a corticosteroid to the local anesthetic is recommended in greater occipital nerve block for cluster headache; ilioinguinal, iliohypogastric and genitofemoral nerve block for post-herniorrhaphy pain; and injection for Morton's neuroma pain.
- ⇒ The addition of a corticosteroid to the local anesthetic is not recommended in sympathetic nerve blocks; greater occipital nerve block for medication overuse headache or migraine; pudendal nerve block for pudendal neuralgia; injection for carpal tunnel syndrome; and trigger point injections.

**Results** This guideline deals with the use and safety of corticosteroid injections for sympathetic, peripheral nerve blocks and trigger point injections for adult chronic pain conditions. All the statements and recommendations were approved by all participants after four rounds of discussion. The Practice Guidelines Committees and Board of Directors of the participating societies also approved all the statements and recommendations. The safety of some procedures, including stellate blocks, lower extremity peripheral nerve blocks and some sites of trigger point injections, is improved by imaging guidance. The addition of non-particulate

corticosteroid to the local anesthetic is beneficial in cluster headaches but not in other types of headaches. Corticosteroid may provide additional benefit in transverse abdominal plane blocks and ilioinguinal/iliohypogastric nerve blocks in postherniorrhaphy pain but there is no evidence for pudendal nerve blocks. There is minimal benefit for the use of corticosteroids in trigger point injections.

**Conclusions** In this practice guideline, we provided recommendations on the use of corticosteroids in sympathetic blocks, peripheral nerve blocks, and trigger point injections to assist clinicians in making informed decisions.

## SYMPATHETIC BLOCKS, PERIPHERAL NERVE BLOCKS AND TRIGGER POINT INJECTIONS FOR CHRONIC PAIN AND ADDITION OF CORTICOSTEROID

Sympathetic blocks are performed for sympathetic-mediated pain including complex regional pain syndrome (CRPS), visceral pain such as pancreatitis, and as prognostic blocks prior to neurolytic blocks in abdominal and pelvic cancers. Peripheral nerve blocks (PNBs) are performed to relieve pain and help reduce the use of pharmacological analgesics. Pain relief from PNBs may outlast the duration of local anesthetic (LA) sensory blockade, indicating that the therapeutic benefit may be a result of mechanisms in addition to pharmacological blockade. This was evidenced by a review of case reports showing complete or greater than 50% pain relief for weeks, and for as long as 7 months.<sup>1</sup> Another study showed that after a greater occipital nerve block (ONB), the mean relief for complete response was 9 days for migraine and 17 days for cluster headache.<sup>2</sup>

Clinicians often add corticosteroid to nerve blocks for its anti-inflammatory effect and corticosteroid's ability to block ectopic neural discharges and nociceptive C fibers. Corticosteroids inhibit the synthesis and activity of cytokines which are powerful mediators of inflammation.<sup>3</sup> Corticosteroids repress ectopic neural discharges in experimental neuromas<sup>4</sup> and depress heat hyperalgesia and mechanoallodynia in an animal nerve injury model.<sup>5</sup> Additionally, topical administration of methylprednisolone has been shown to reversibly block transmission of C fibers but not A-beta fibers in rat plantar nerves.<sup>6</sup>

There has not been a practice guideline (PG) that looked into the efficacy and safety of corticosteroid injections in PNBs, joints and neuraxial injections in adult patients with chronic pain. In this PG, we discuss the role of corticosteroids in sympathetic nerve blocks, PNBs, and trigger point injections (TPIs) for chronic, not acute or perioperative pain. The other PGs will review corticosteroid injections for joints and neuraxial corticosteroid injections and associated topics, such as safety of the injection in the presence of anticoagulants and interaction of the corticosteroid injection with vaccines.

## DEVELOPMENT OF THE PG ON THE USE OF CORTICOSTEROIDS IN SYMPATHETIC AND PNBs, AND TPIs FOR ADULT CHRONIC PAIN

The topics were identified by a Work Group and assigned to participants who had written on the subject matter or had interest in the issue. Each topic author performed an extensive literature search using PubMed, Embase, and/or Cochrane Clinical Trials with appropriate medical subject headings (MeSH) terms on each topic (see online supplemental appendix). Based on qualitative evidence synthesis, statements and recommendations (SRs) were formulated using the United States Preventive Services Task Force levels of evidence (table 1). The SRs were

**Table 1** United States Preventive Services Task Force (USPSTF) Grades and Levels of Certainty Regarding Net Benefit

Grade	Definitions
A	The USPSTF recommends the service. There is high certainty that the net benefit is substantial.
B	The USPSTF recommends the service. There is high certainty that the net benefit is moderate, or there is moderate certainty that the net benefit is moderate to substantial.
C	The USPSTF recommends selectively offering or providing this service to individual patients based on professional judgment and patient preferences. There is at least moderate certainty that the net benefit is small.
D	The USPSTF recommends against the service. There is moderate or high certainty that the service has no net benefit or that the harms outweigh the benefits.
I	The USPSTF concludes that the current evidence is insufficient to assess the balance of benefits and harms of the service. Evidence is lacking, of poor quality, or conflicting, and the balance of benefits and harms cannot be determined.
Level of certainty	Description
High	The available evidence usually includes consistent results from well-designed, well-conducted studies in representative primary care populations. These studies assess the effects of the preventive service on health outcomes. This conclusion is therefore unlikely to be strongly affected by the results of future studies.
Moderate	The available evidence is sufficient to determine the effects of the preventive service on health outcomes, but confidence in the estimate is constrained by such factors as: the number, size, or quality of individual studies, inconsistency of findings across individual studies, limited generalizability of findings to routine primary care practice, lack of coherence in the chain of evidence. As more information becomes available, the magnitude or direction of the observed effect could change, and this change may be large enough to alter the conclusion.
Low	The available evidence is insufficient to assess effects on health outcomes. Evidence is insufficient because of the limited number or size of studies, important flaws in study design or methods, inconsistency of findings across individual studies, gaps in the chain of evidence, findings not generalizable to routine primary care practice, and lack of information on important health outcomes. More information may allow estimation of effects on health outcomes.
The USPSTF defines certainty as 'likelihood that the USPSTF assessment of the net benefit of a preventive service is correct'. The net benefit is defined as benefit minus harm of the preventive service as implemented in a general, primary care population. The USPSTF assigns a certainty level based on the nature of the overall evidence available to assess the net benefit of a preventive service. From: Harris <i>et al.</i> <sup>7</sup>	

unanimously approved by the participants using a modified Delphi process after four rounds of voting.<sup>7-9</sup> Subsequently, these SRs were approved by the Board of Directors of the participating societies. This PG was sponsored by the American Society of Regional Anesthesia and Pain Medicine and approved by the participating societies including the American Academy of Pain Medicine, American Society of Interventional Pain Physicians, International Pain and Spine Intervention Society, and North American Spine Society. The American Academy of Orthopaedic Surgeons and the American Academy of Physical Medicine and Rehabilitation sent a knowledgeable resource member (JR and AN respectively) to help develop the PG.

## SYMPATHETIC NERVE BLOCKS

Sympathetic nerve blocks provide temporary and occasionally long-term relief of pain for patients with presumed sympathetically maintained pain. These blocks may be performed with

fluoroscopy, ultrasound (US) guidance or landmark techniques (ie, blind), but most studies use some form of imaging guidance. There is no convincing evidence to recommend one type of imaging technique over the other. A pilot study of 10 cadavers compared US with fluoroscopy in stellate ganglion block. The investigators noted better successful staining of the sympathetic trunk with US (9 of 10 cadavers) compared with fluoroscopy (6 of 10). The lack of statistical significance ( $p=0.303$ ) may be due to small number of cadavers studied.<sup>10</sup> A few studies specifically focused on safety and comparative effectiveness. Although clinicians have attempted to use various adjuvant drugs (eg, clonidine, dexmedetomidine) to enhance and/or prolong the effect of LA used for sympathetic blocks, the focus of this section is to summarize the evidence regarding the use of corticosteroids and imaging techniques.

### ROLE OF FLUOROSCOPY, US, AND CONTRAST MEDIA TO MINIMIZE SIDE EFFECTS

There were 56 publications reporting the use of corticosteroids in sympathetic blocks, 48 of which were case reports. A total of 49 studies used imaging guidance: endoscopic ultrasound (EUS) in 12, fluoroscopy in 22, US in 11, CT in 3, and MRI in 1. EUS was compared with fluoroscopic guided celiac plexus block in 56 patients,<sup>11</sup> and the authors found that injections with EUS guidance provided longer term pain relief. No other study compared the impact of the different imaging techniques on efficacy.

### USE OF CORTICOSTEROIDS IN SYMPATHETIC BLOCKS

Corticosteroids used in studies included methylprednisolone in 17, triamcinolone in 29, and dexamethasone in 9; 1 investigation did not report the type of corticosteroid used. No study compared the different steroids.

### STUDIES EVALUATING SYMPATHETIC BLOCKS WITH LA PLUS CORTICOSTEROIDS

In a retrospective chart review of 11 patients with chronic pancreatitis receiving a 40–80 mg methylprednisolone injection around the celiac plexus using fluoroscopy, 6 patients obtained pain relief lasting an average of 11.4 weeks with either single or multiple blocks.<sup>12</sup> Busch *et al* reviewed the charts of 16 patients with chronic pancreatitis who received a mixture of bupivacaine and depot corticosteroid (corticosteroid details not reported) using fluoroscopy, and only 4 patients experienced pain relief.<sup>13</sup>

A retrospective analysis used an EUS database of 36 celiac ganglia injections in 33 patients who had pain from pancreatic cancer or chronic pancreatitis. Seventeen patients with pancreatic cancer pain experienced benefit with alcohol neurolysis (94%) while one patient who received 80mg methylprednisolone experienced no relief. Among the patients with chronic pancreatitis pain, 4/5 patients (80%) had pain relief with alcohol neurolysis versus 4 of 13 (38.5%) who received 80mg methylprednisolone.<sup>14</sup> The duration of pain relief was not documented.

A retrospective evaluation of 29 patients with coccydynia receiving ganglion impar block under fluoroscopy with bupivacaine and 40mg of methylprednisolone showed that 20 out of 29 patients had decreased pain severity as measured by the visual analog scale (VAS) at 3 and 6 months.<sup>15</sup> The remaining nine patients went on to receive a pulsed radiofrequency ablation (RFA), leading to a longer duration (1 year) of decreased pain scores.

A randomized study in patients with coccydynia showed that ganglion impar block with bupivacaine, saline and 40mg methylprednisolone was more effective than caudal injection of

bupivacaine, saline and 80mg triamcinolone.<sup>16</sup> Both resulted in significant pain relief from baseline; the relief was significantly better with the ganglion impar group at 3 weeks but not at 3 months.

### STUDIES OF SYMPATHETIC BLOCKS COMPARING LA TO CORTICOSTEROID OR COMBINED INJECTATE

A retrospective study compared lumbar sympathetic blocks performed under fluoroscopic or CT guidance and using either 10 mL 0.25% bupivacaine or bupivacaine with 40 mg of triamcinolone in patients with cancer and abdominopelvic pain ( $n=11$ ) and leg pain ( $n=40$ ).<sup>17</sup> Among those with abdominopelvic pain, effectiveness was nearly similar in those with (83%) and without corticosteroid (80%), with similar duration of relief. Among those with leg pain, LA alone provided pain relief in 68% and LA with steroid provided 83% pain relief along with increased duration.<sup>17</sup>

A double-blind randomized controlled trial (RCT) of 64 patients with facial pain from acute herpes zoster received stellate ganglion block under fluoroscopy with 6 mL normal saline or 6 mL 0.125% bupivacaine with 8 mg of dexamethasone. Shorter duration of pain and lower incidence of postherpetic neuralgia was reported in the LA plus steroid group.<sup>18</sup> Interestingly, 22 patients reported no pain in the saline group even at 6 weeks. It should be noted that signs of sympathetic blockade, including Horner's syndrome (indicative of superior cervical ganglion blockade), nasal stuffiness and increased skin temperature, as well as relief of pain, have been noted after stellate ganglion block with saline.<sup>19</sup> The authors theorized that pressure on the stellate ganglion by the prevertebral fascia could explain the "nerve blockade" from saline alone.

A single-center blinded RCT of EUS-guided celiac plexus block comparing bupivacaine alone versus bupivacaine and triamcinolone 80mg in 40 patients with chronic pancreatitis reported no difference in the pain disability index between groups.<sup>20</sup>

An RCT of 36 patients with CRPS compared subcutaneous injection versus fluoroscopic-guided thoracic sympathetic block at T2 level of 5-mL ropivacaine and 5-mL triamcinolone (2%). Although the Brief Pain Inventory score was not significantly different at 1 month, it was significantly lower at 12 months in the sympathetic block group.<sup>21</sup>

In a dose comparison RCT, Park *et al* compared 0.5% bupivacaine 5 mL; 0.5% bupivacaine 4.5 mL + 20mg of triamcinolone 0.5 mL; and 0.5% bupivacaine 4 mL + 40mg of triamcinolone 1 mL in decreasing breast cancer-related lymphedema (upper arm and forearm circumference) following stellate ganglion block in 32 patients.<sup>22</sup> Although all groups trended toward a decrease in arm circumference, the group receiving 40-mg triamcinolone with bupivacaine showed significantly decreased upper arm circumference compared with the bupivacaine alone group.

### ADVERSE EVENTS

EUS-guided celiac plexus blocks have a reported complication rate of 1.6%.<sup>23</sup> O'Toole *et al* reviewed records of 220 patients who received either celiac plexus neurolysis with alcohol ( $n=31$ ) or celiac plexus blocks with steroids ( $n=189$ ). One patient had prolonged hypotension. Another patient developed retroperitoneal abscess at 4 weeks after a repeat block and was treated with percutaneous drainage, while two patients developed severe postprocedure pain.<sup>23</sup> Another case of retroperitoneal abscess following EUS-guided celiac plexus block with 20 mL 0.25% bupivacaine and 20mg triamcinolone has been reported in a patient treated for sclerosing mesenteritis.<sup>24</sup>



Olson *et al* reported a case of steroid-induced mania in a patient after the fourth injection in a series of EUS-guided celiac plexus blocks with triamcinolone and bupivacaine, performed in a 4-month period.<sup>25</sup> The patient noticed racing thoughts for 2 weeks, which resolved spontaneously. Four months later, the patient underwent a fifth injection and developed symptoms of mania, depression and anxiety. She was treated with clonazepam and lithium and diagnosed with bipolar disorder and steroid-induced psychosis.<sup>25</sup>

A case of transient cauda equina syndrome was reported in a patient with rectal cancer following fluoroscopic-guided ganglion impar neurolysis with 6 mL of 50% alcohol, 0.25% bupivacaine, and 40-mg triamcinolone.<sup>26</sup> The deficit was noted 3 hours after the procedure; the patient slowly regained bowel and bladder function over the subsequent 24 hours but had persistent sensory loss over the S1 dermatome. Another case of conus infarction, confirmed by MRI, occurred after a non-image guided ganglion impar block using 40 mg of triamcinolone and bupivacaine 4 mL.<sup>27</sup> The patient recovered motor function within 24 hours but at 6 months follow-up, continued to have sensory symptoms including tingling, heaviness, and subjective weakness. The neurological insult may have been due to spasm of a radicular artery or embolization of the particulate corticosteroid. Note that the artery of Adamkiewicz originates as low as L4, L5, or S1<sup>28</sup> and may arise from lateral or middle sacral arteries in proximity to the ganglion impar.<sup>29</sup>

## SUMMARY OF STUDIES

There is no convincing evidence to recommend one type of imaging over another. However, US guidance is favored for superficial structures adjacent to blood vessels (eg, stellate ganglion) and fluoroscopy is preferred for deeper axial structures (eg, lumbar sympathetic block). Multiple studies show that sympathetic blocks with LA alone, without corticosteroid, may be adequate for pain relief.

In light of the poor quality of previous studies, there is a need for well-designed studies to assess the benefit and potential for adverse events with addition of corticosteroids to sympathetic nerve blocks. The addition of particulate corticosteroid to LA is not recommended in stellate ganglion blocks because of possible cerebral embolism of the particulate corticosteroid via unintentional injection into the vertebral artery.

Statements and recommendations are presented in [box 1](#).

The statements apply to sympathetic blocks and PNBs for *relief of chronic pain, not acute or perioperative pain*. The recommendations assume that the practitioner has adequate technical knowledge of the use of US for performing the nerve blocks.

## OCCIPITAL NERVE BLOCK

The greater occipital nerve (GON) arises from the medial branch of the dorsal ramus of C2 and ascends the obliquus capitis inferior and semispinalis muscle before piercing the semispinalis. It travels through the trapezius muscle near the superior nuchal ridge and divides into superficial terminal branches, ending medial to the occipital artery. The GON provides sensory innervation from the external occipital protuberance to the vertex of the posterior scalp.<sup>30</sup> GON blocks may be used as diagnostic and therapeutic treatment strategies in primary and secondary headaches.<sup>31 32</sup>

## Box 1 Statements and recommendations on the safety of steroid injections in sympathetic nerve blocks

### Statements

1. Sympathetic blocks may provide pain relief with or without the addition of corticosteroid in the injectate.  
*Level of certainty: moderate*
2. Use of particulate corticosteroids in stellate ganglion blocks may cause central nervous system injury.  
*Level of certainty: low*
3. Reported pain relief after stellate ganglion block is similar if performed under fluoroscopy or ultrasound guidance.  
*Level of certainty: moderate*
4. Image guidance may help decrease complications and improve accuracy of sympathetic blocks, including visceral sympathetic blocks.  
*Level of certainty: moderate*

### Recommendations

1. Local anesthetic alone is sufficient for performing sympathetic blocks for pain relief.  
*Grade C*
2. Imaging guidance with ultrasound or fluoroscopy is recommended for the performance of sympathetic blocks, with ultrasound permitting visualization of vascular structures.  
*Grade B*

## TECHNIQUES

### Landmark technique

Several techniques have been described for blocks being performed using non-image guided landmark anatomy.<sup>33–38</sup> Targeting the nerve based on anatomic landmarks may not be accurate due to anatomical variants.<sup>39</sup> Another study found high variability in the distance from the GON to the midline at a horizontal level between the external occipital protuberance and the mastoid process in 100 cadavers.<sup>36</sup>

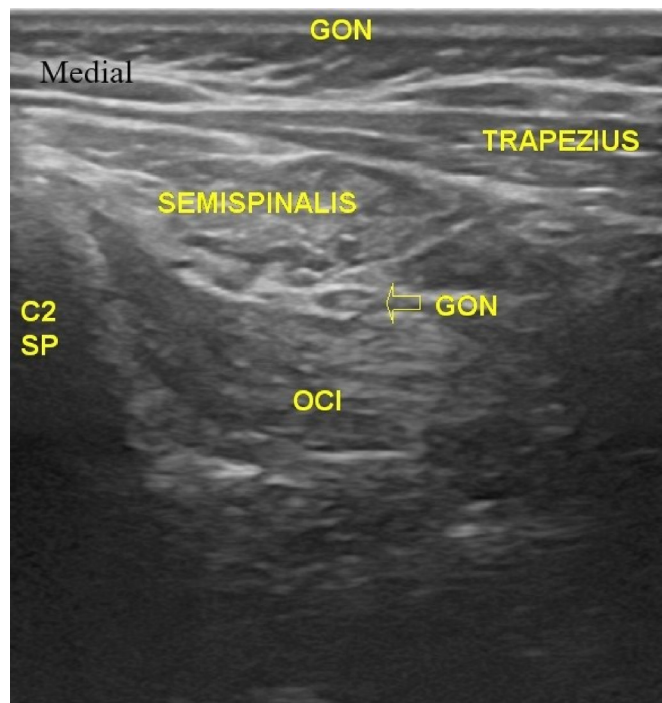
### Image-guided ONB

The use of fluoroscopy has been described in performing GON blocks in the suboccipital compartment.<sup>40–42</sup> In a double-blinded RCT, the non-image-guided landmark technique resulted in 2 weeks of analgesia compared with 24 weeks after the fluoroscopic suboccipital compartmental technique.<sup>42</sup>

US-guided GON blocks have been described in the literature.<sup>43–49</sup> US guidance can facilitate the visualization of small peripheral nerves and real-time needle localization for a more precise deposition of the injectate<sup>50 51</sup> that is critical for diagnostic injections.<sup>52</sup> Two different techniques have been described for GON blocks: the classic/distal and the proximal approach.<sup>47</sup> The proximal approach requires US guidance in view of the required landmarks (C2 spinous process, obliquus capitis inferior muscle) ([figure 1](#)).

A double-blinded placebo-controlled RCT<sup>44</sup> and a case report<sup>48</sup> demonstrated a high success rate with US-guided GON blocks using the classic/distal approach. An RCT found US-guided GON block using the classic/distal approach to be a more effective technique than the blind landmark anatomic approach.<sup>46</sup>

A prospective open-label study demonstrated successful US-guided GON block using the proximal approach with significant reduction in pain scores.<sup>49</sup> When comparing US-guided



**Figure 1** Proximal occipital nerve block with ultrasound guidance. The C2 spinous process is bifid; the relationship between the greater occipital nerve (GON) and obliquus capitis inferior (OCI) muscle is constant. Image provided by Hariharan Shankar, MD.

ONBs using the classic/distal approach to the proximal approach, a cadaver study found a higher success rate with the proximal approach based on the nerve being successfully covered with dye.<sup>47</sup> A double-blinded RCT found that both the distal and proximal approach provide short-term improvement in headache intensity. The proximal approach may provide more sustained benefit compared with the distal approach.<sup>43</sup>

### Nerve stimulator technique

A double-blind, placebo-controlled RCT utilizing nerve stimulator guidance to block the GON, and lesser occipital nerve showed superior efficacy with LA compared with saline.<sup>45</sup> Correct needle placement was identified by a tingling sensation in the distribution of the GON. The authors commented that the nerve stimulator technique can identify the location of the GON rather than infiltrating the “general location”.

### ADDITION OF CORTICOSTEROID TO ONBS

#### Case series and reports

A case series of 16 patients with cluster headaches who underwent GON blocks with methylprednisolone 160mg indicated that 9 out of 16 patients responded favorably.<sup>53</sup>

Several case reports have described benefits received from GON blocks with particulate and non-particulate corticosteroids. A case of cluster headache was aborted with betamethasone and LA,<sup>54</sup> basilar type migraines with triamcinolone and LA,<sup>55</sup> atypical cluster headache with trigeminal symptoms with betamethasone and LA,<sup>56</sup> migraines with varying doses of methylprednisolone alone,<sup>57</sup> menstrual migraines with triamcinolone and LA,<sup>58</sup> hemiplegic migraine aura with triamcinolone and LA,<sup>59</sup> and chronic occipital headaches with methylprednisolone and LA.<sup>48</sup> The above case reports and case series support the

### Box 2 Statements and recommendations on the safety of corticosteroid injections in greater occipital nerve blocks

#### Statements

1. The proximal approach has only been described with an ultrasound technique. Image guidance may improve the efficacy of the distal approach to greater occipital nerve blocks compared with a non-image-guided approach.  
*Level of certainty: low*
2. With ultrasound guidance, both the classic/distal approach and the proximal approach appear to be effective for greater occipital nerve blocks.  
*Level of certainty: moderate*
3. The proximal approach may provide more sustained benefit compared with the distal approach.  
*Level of certainty: low*
4. The addition of corticosteroid to the local anesthetic improve outcomes compared with local anesthetic alone or saline when performing greater occipital nerve blocks for patients with cluster headaches.  
*Level of certainty: moderate*
5. Local anesthetic alone yields similar outcomes compared with local anesthetic with corticosteroid when performing greater occipital nerve blocks for patients with migraine and medication overuse headaches.  
*Level of certainty: moderate*

#### Recommendations

1. Consider using ultrasound when performing greater occipital nerve blocks. Clinicians may choose either the classic/distal or the proximal approach to greater occipital nerve block, but the latter should be performed with ultrasound guidance.  
*Grade A*
2. The addition of corticosteroid to the local anesthetic is preferred in greater occipital nerve blocks for cluster headache.  
*Grade C*
3. Clinicians should avoid the use of corticosteroids in greater occipital nerve blocks for migraine and medication overuse headache.  
*Grade D*
4. Clinicians should monitor and limit the number and frequency of greater occipital nerve blocks with corticosteroids to avoid side-effects.  
*Grade B*

efficacy of GON blocks with LA and corticosteroid injection in patients with headache.

#### Observational studies

A total of 15 observational studies, 6 retrospective and 9 prospective, have been published evaluating the efficacy of particulate and non-particulate corticosteroids when performing GON blocks. In a retrospective study of 60 patients with cluster headaches receiving a total of 121 GON blocks with betamethasone and LA, 45% (54/121) demonstrated a complete response after the block, 35% (42/121) a partial response, and 21% (25/121) had no relief. The authors reported more benefit for patients that suffer from episodic versus chronic cluster headaches.<sup>60</sup>

Another study evaluated GON blocks with methylprednisolone and LA in patients with headaches: cluster headaches (n=19), migraine (n=54), new daily persistent headaches

### Box 3 Statements and recommendations on safety of corticosteroid injections in chest wall blocks, transversus abdominis plane blocks, and ilioinguinal/iliohypogastric nerve blocks

#### Statements

##### Chest wall blocks

1. Image-guided techniques are more accurate than landmark techniques. With US, one can visualize the target tissue and the pleura while one can better mark the levels with fluoroscopy.

*Level of certainty: high*

2. There are no significant differences in outcomes between US-guided and fluoroscopy-guided intercostal and paravertebral injections.

*Level of certainty: high*

3. Patient-specific clinical data, including diagnosis, comorbidities, response to previous injections, and other relevant clinical information determine the frequency and number of blocks.

*Level of certainty: low*

#### Recommendations

1. An image-guided technique is preferred for intercostal and paravertebral blocks to improve accuracy of injections.

*Grade C*

2. US guidance is preferable to fluoroscopy for intercostal and paravertebral injections because the pleura and target tissue are visualized.

*Grade C*

3. Non-particulate corticosteroids are preferred over particulate corticosteroids for proximal intercostal or paravertebral injections to avoid the rare risk of vascular uptake that may result in spinal cord injury.

*Grade C*

##### Transversus abdominis plane blocks

#### Statements

1. Transversus abdominis plane blocks with ultrasound guidance are more accurate than landmark-based techniques.

*Level of certainty: moderate*

#### Recommendations

1. Transversus abdominis plane blocks are preferably conducted with ultrasound to ensure accurate placement of injectate.

*Grade B*

##### Ilioinguinal/iliohypogastric nerve blocks

#### Statements

1. Ilioinguinal/iliohypogastric blocks performed under ultrasound are more accurate than landmark-guided techniques.

*Level of certainty: moderate*

2. Ilioinguinal/iliohypogastric injections performed with image-based or landmark-based techniques have similar efficacy and safety outcomes.

*Level of certainty: low*

#### Recommendations

1. Clinicians may consider ultrasound guidance for ilioinguinal/iliohypogastric injections for more accurate placement.

*Grade B*

(n=10), hemicrania continua (n=7), and other headaches (n=11). For migraine, the block provided a complete or partial response in 46% of the injections, with the complete and partial

responses lasting for a mean of 9 and 61 days, respectively.<sup>2</sup> This compared with 59% in patients with cluster headache, with complete and partial responses lasting for a mean of 17 and 52 days, respectively. The corresponding responses were 63% for new daily persistent headaches, 60% for hemicrania, and 64% for other headache types.<sup>2</sup>

A 1992 retrospective study of patients with migraine (n=97) and post-traumatic headache (n=87) receiving GON blocks with methylprednisolone and LA reported significantly higher response rates in patients with post-traumatic headache (72%) compared with patients with migraine (54%).<sup>61</sup> Another 1992 retrospective study of methylprednisolone 160mg injection reported a similar response rate in 50 patients with migraine with GON "irritation" (88%) and 86 patients with "occipital neuralgia" (87%), with a mean duration of 32 and 31 headache-free days, respectively.<sup>62</sup>

A retrospective study investigated the efficacy of GON blocks for specific headache types with or without symptomatic medication overuse reported a failure rate of 22% of the 108 blocks performed with LA and methylprednisolone. In 78% of the injections, the mean decrease in head pain was 83% and lasted for a mean of 6.6 weeks.<sup>57</sup>

A retrospective study of 21 patients who received at least 3 GON blocks with methylprednisolone and lidocaine for cervicogenic headaches in a 6-month timeframe reported a significant decrease in pain scores. The mean pain scores before and after injection were  $6.71 \pm 0.64$  and  $1.48 \pm 0.93$  ( $p < 0.001$ ).<sup>63</sup>

#### Prospective observational studies

A prospective observational study evaluated the effects of greater and lesser ONBs with methylprednisolone versus LA versus intramuscular methylprednisolone in patients with cervicogenic headaches, chronic cluster headaches, and migraine headaches. In patients with cervicogenic headaches, 94% (169/180) had a mean duration of relief for 23.5 days with the corticosteroid group vs 84% (42/50) who had a maximum duration of relief of 1.6–3 hours in the LA alone group, and none (0/50) experienced relief with intramuscular injections. For patients with chronic cluster headaches, 100% (20/20) experienced relief with methylprednisolone versus 80% (16/20) with LA. For migraine headaches, 90% (18/20) experienced relief with methylprednisolone versus 80% (16/20) with LA.<sup>64</sup> Another prospective observational study evaluated 112 patients with sustained headache syndrome associated with tender occipital nerve zones who had 188 headache episodes where they received GON blocks with betamethasone and LA. Relief was transient or not obtained in 35% and was prolonged in 65% of the 188 headache episodes receiving injection.<sup>65</sup>

Several observational studies reported relief from ONBs in patients with cluster headaches. A prospective observational study of 20 patients with cluster headaches receiving GON blocks with methylprednisolone and LA and concluded that local corticosteroid injections could arrest bouts of attacks for a period ranging from 5 to 73 days.<sup>66</sup> Another prospective observational study in 14 patients with cluster headaches who had GON blocks with triamcinolone and LA reported that 29% of the patients were headache free for a mean of 42 days, 36% were headache free for a mean of 3 days, and 36% had no response. The authors reported the headache intensity, frequency, and duration were significantly decreased in the postinjection week compared with the week prior to the nerve block.<sup>67</sup> In a third prospective observational study of 83 patients who received GON blocks with methylprednisolone and LA for chronic cluster



#### Box 4 Statements and recommendations on the safety of corticosteroid injections in upper extremity and lower extremity injections

##### Upper extremity injections—carpal tunnel syndrome

###### Statements

1. Ultrasound guidance for *carpal tunnel syndrome* injections confer a small benefit as compared with landmark-based injections regarding functional improvement and pain.

*Level of certainty: low*

###### Recommendations

1. Clinicians may consider *carpal tunnel injections* with ultrasound guidance.

*Grade C*

##### Lower extremity injections

###### Statements

1. For lower extremity peripheral nerve injections, ultrasound guidance is superior to nerve stimulator guidance and landmark-based techniques with regards to pain reduction.

*Level of certainty: high*

2. The use of corticosteroid adjuvants in pudendal nerve blocks for the management of pain of chronic pudendal neuralgia does not prolong the benefit of an injection performed with local anesthetic alone.

*Level of certainty: moderate*

3. Results are better when Morton's neuroma injections are done under US compared with landmark technique.

*Level of certainty: moderate*

4. Morton's neuroma injections with corticosteroids have a 50% likelihood of achieving satisfactory relief at a 1-year follow-up.

*Level of certainty: moderate*

###### Recommendations

1. Clinicians should preferably use ultrasound guidance, compared with nerve stimulator guidance and landmark-based techniques, when performing lower extremity peripheral nerve injections given the improved efficacy compared with other forms of visualization.

*Grade A*

2. When performing pudendal nerve injections for chronic pudendal neuralgia, clinicians should consider avoiding the use of corticosteroids as they do not prolong the benefit associated with local anesthetic alone.

*Grade D*

3. Morton's neuroma injections should be performed with ultrasound guidance rather than landmark-based guidance.

*Grade C*

4. When performing Morton's neuroma injections, clinicians should use corticosteroids with the local anesthetic.

*Grade B*

Please see text for comparative efficacy of corticosteroid to other injectates in carpal tunnel syndrome

headache, a positive response was observed in 57% (47/83) of patients. A total of 42% (35/83) were pain free, 15% (12/83) had a partial benefit, and one patient obtained <50% improvement. The duration of response lasted a median of 21 days.<sup>68</sup>

In a prospective observational study of 19 patients with migraine receiving a GON block and TPIs with triamcinolone and LA, 89.5% had symptom relief with reduction of pain scores from 6.5 to 3.5, 20 min after the injection.<sup>69</sup> In another

prospective observational study in patients with chronic migraine, 150 patients with unilateral (n=37) or bilateral (n=113) GON blocks with triamcinolone and LA were observed for 30 days. Over half of the patients (78/150) reported a 50% or greater reduction in headache days per month over 30 days following treatment relative to the 30 days pretreatment baseline.<sup>70</sup> A third prospective observational study examined the effect of bilateral ONBs with lidocaine, bupivacaine, and methylprednisolone in patients with chronic migraine. Pain intensity decreased from a mean of 7.33 to 4.80 for up to 3 months. The average weekly number of total migraine attacks declined from 4.15 to 1.56 attacks per week.<sup>71</sup>

In 15 patients with chronic tension headache, a prospective observational study reported the lack of headache relief with GON block consisting of LA and dexamethasone. Eleven of the 15 patients had no relief of symptoms, 3 had worsening headaches, and 1 had worsened headaches for 2 days before reporting some relief.<sup>72</sup>

In summary, retrospective studies support the addition of corticosteroid to ONBs for cluster headache. For migraine, the benefit shown in retrospective and observational studies was not confirmed in RCTs, as described below.

##### Randomized controlled studies

The addition of corticosteroid appears to improve the efficacy of ONBs in cluster headache. A double-blind, placebo-controlled study found 11/13 (85%) of the patients who received lidocaine with betamethasone became attack free compared with none of 10 patients in lidocaine alone group for cluster headaches ( $p < 0.0001$ ).<sup>73</sup> Another double-blind RCT found that 20 out of 21 patients with cluster headaches who received 3 injections with cortivazol, 48–72 hours apart, had a reduction of the number of daily attacks to a mean of 2 or fewer in 72 hours compared with 12 out of 22 patients in the placebo arm (OR, 14.5; 95% CI 1.8 to 116.9;  $p = 0.012$ ).<sup>74</sup>

In contrast to cluster headache, added benefit from corticosteroid in the LA was not noted in patients with migraine. A single-blinded RCT did not find improved efficacy with addition of triamcinolone to lidocaine and bupivacaine (group A) compared with lidocaine and bupivacaine with normal saline (group B) when GON blocks were performed for 37 patients with transformed migraine. Both groups had an equivalent and statistically significant reduction in pain. Mean headache severity decreased by 3.1 points in group A ( $p < 0.01$ ) and 3.2 points in group B ( $p < 0.01$ ).<sup>38</sup> A double-blind RCT found patients who received ONBs for short-term preventive treatment of migraines with bupivacaine and methylprednisolone (n=33) compared with lidocaine with a normal saline placebo (n=30) had no significant difference in the frequency of moderate or severe migraine headaches.<sup>75</sup> In the active and placebo groups, the mean frequency of at least moderate (9.8 vs 9.5) and severe (3.6 vs 4.3) migraine days and acute medication days (7.9 vs 10.0) were not substantially different at baseline. The percentage of patients with at least a 50% reduction in the frequency of moderate or severe headache days was 30% for both groups (10/30 vs 9/30).<sup>75</sup> Another double-blind RCT was conducted on patients who suffer from migraine headaches. Patients were assigned to receive triamcinolone and lidocaine (n=24) or lidocaine with normal saline (n=24) with no significant differences found in pain severity, frequency, and times to analgesic use between the two groups. Both groups had a decrease in all 3 variables within 2 weeks of the injection.<sup>76</sup>

**Box 5 Statements and recommendations on the safety of corticosteroid use in trigger point injections****Statements**

1. Ultrasound can visualize neurovascular structures and may result in more accurate targeting of trigger point injections in deeper anatomic locations  
*Level of certainty: moderate*

**Recommendations**

1. Trigger point injections can be conducted based on palpation alone or with ultrasound, which may improve accuracy of injection.  
*Grade C*
2. Clinicians may consider ultrasound guidance for trigger point injections conducted in areas near high-risk tissues (risk of neural, vascular, pulmonary, or visceral injury) or in trigger points located in deeper anatomic locations  
*Grade C*

**Statements**

1. The addition of corticosteroid to a local anesthetic does not result in increased benefit that outweighs the potential risks.  
*Level of certainty: moderate*

**Recommendations**

1. The use of local anesthetic alone should be considered for trigger point injections.  
*Grade B*

A double-blind RCT study of 32 patients with medication overuse headaches received GON blocks with methylprednisolone and bupivacaine versus bupivacaine and normal saline.<sup>77</sup> The mean reduction in headache severity after 1 hour was  $4.63 \pm 1.92$  in the methylprednisolone and bupivacaine group versus  $5.56 \pm 1.03$  in the bupivacaine and normal saline group. The average days without headache in the first month after the injection was 4.75 in the methylprednisolone and bupivacaine group and 8.75 days in the bupivacaine and normal saline group. There was no statistical significance between groups.<sup>77</sup>

In summary, RCTs show that the salutary effect of adding a corticosteroid to ONBs depends on the type of headache, with greater efficacy in cluster headache relative to migraine and/or medication overuse headache. The mechanisms underlying these differences are unclear.

**POTENTIAL ADVERSE EFFECTS FROM CORTICOSTEROID**

Subcutaneous injection of triamcinolone acetate in healthy volunteers was found to cause local atrophy.<sup>78</sup> A few case reports and a retrospective review described full-thickness soft-tissue atrophy, alopecia, and hyperpigmentation when using particulate steroids.<sup>2 68 79 80</sup> The mechanism is thought to be due to vasoconstriction and deposits of the insoluble corticosteroid crystals at the site of injection.<sup>81</sup> The risk of cutaneous complications may depend on the depth of the injection, and it has been suggested that deeper injections are associated with lower risk.<sup>82</sup> Highly soluble, non-particulate corticosteroids should be preferentially selected for superficial soft-tissue injections.<sup>83</sup>

There is a risk of systemic side-effects from repeated corticosteroid injections. Intradermal injection administration of corticosteroids has been implicated in the development of Cushing syndrome.<sup>84</sup> A case report described a patient who developed

Cushing syndrome after a series of six ONBs with total administration of 480 mg triamcinolone in 3 months.<sup>85</sup> Another study evaluated a series of three injections with cortivazol 3.75 mg, which is equivalent to 187.5 mg of prednisone, 48–72 hours apart in patients with cluster headaches, and no systemic side effects were reported.<sup>74</sup> Recommendations have been published that suggest the frequency of LA injections may occur once every 2–4 weeks and injection of corticosteroids approximately once every 3 months, with consideration of individual comorbidities.<sup>32</sup>

Statements and recommendations are presented in [box 2](#).

**SUPRAORBITAL NERVE BLOCKS**

The supraorbital nerve is a branch of the ophthalmic division of the trigeminal nerve. It originates from the frontal nerve which is a branch of V1. The supraorbital nerve is accompanied by the supraorbital artery and exits the orbit lateral to the supra-trochlear nerve. The nerve provides sensory innervation to the lateral forehead, upper eyelid, and anterior part of the scalp. Supraorbital nerve blocks have been used to diagnose and treat supraorbital neuralgia.<sup>35</sup>

**Technique**

Supraorbital nerve blocks are usually performed using landmarks. A cadaver study showed the utility of US guidance, with the supraorbital notch identified as a defect in the orbital ridge.<sup>86</sup> The authors noted that the accuracy rates were 100% (18 of 18 injections) for the in-plane approach compared with 94% (17 of 18) with the out-of-plane approach. There are no studies comparing efficacy of a non-image-guided versus a US-guided approach to performing the supraorbital nerve block.

**ADDITION OF CORTICOSTEROIDS IN SUPRAORBITAL NERVE BLOCKS**

The use of corticosteroids for supraorbital nerve blocks has not been described in the literature. Prospective observational trials and case series and reports describe use of LA without corticosteroids.<sup>87–91</sup>

**POTENTIAL SIDE-EFFECTS FROM CORTICOSTEROIDS**

Given the lack of published literature regarding use of corticosteroids in supraorbital nerve blocks, there are no reported corticosteroid-related adverse effects specific to these blocks. However, cutaneous side-effects of corticosteroid injections are possible due to the superficial location of the supraorbital nerve.

**Statements and recommendations**

As noted, published studies on supraorbital nerve blocks involved LA only. Hence, the effect of adding corticosteroids to LA for supraorbital nerve blocks is unknown. Because of the nerve's superficial location, particulate corticosteroids should probably not be used in supraorbital nerve blocks. Clinicians may consider using US guidance to avoid intraforaminal injection. Formal SRs on these issues were not made because of the absence of published studies.

**CHEST WALL (INTERCOSTAL NERVE BLOCK, PARAVERTEBRAL NERVE BLOCK)**

Intercostal and paravertebral blocks are used to provide relief for patients with rib fractures, painful herpes zoster, postherpetic neuralgia, acute and chronic post-thoracotomy pain, cancer-associated pain, slipped rib syndrome, and others.<sup>18 92–99</sup> These injections permit decreased use of opioids, membrane stabilizers, and other systemic analgesics.



Table 2 Commonly used doses of corticosteroids

Study, reference number	Block/injection	Corticosteroid, dose injected
Peres <i>et al</i> ; Ambrossini <i>et al</i> <sup>67 73</sup>	Greater occipital nerve block, cluster headache*	Triamcinolone, 40 mg Betamethasone dipropionate, 12.46 mg and betamethasone phosphate, 5.26 mg† (study from Italy and Belgium)
Saglam <i>et al</i> ; Okur <i>et al</i> <sup>120 128</sup>	Suprascapular block for chronic shoulder pain	Triamcinolone, 40 mg Triamcinolone, 20 mg
Abd-Elsayed <sup>111 112</sup>	Transversus abdominis plane block for chronic abdominal pain	Triamcinolone, 80 mg (bilateral) Triamcinolone, 40 mg (unilateral)
Khan <i>et al</i> , (scoping review of 5 studies) <sup>117</sup>	Ilioinguinal, iliohypogastric, genitofemoral nerve block for postherniorrhaphy pain	Methylprednisolone, 20 mg Methylprednisolone, 40 mg Triamcinolone, 40 mg Triamcinolone, 80 mg Cortivazol, 3.75 mg (Triamcinolone 50 mg equivalent)
Moya Esteban <sup>193</sup>	Vaginal trigger point injection	Betamethasone acetate, 2 mL† (study from Spain)
Saygi <i>et al</i> ; Markovic <i>et al</i> ; Thomson <i>et al</i> <sup>154–156</sup>	Morton's neuroma	Methylprednisolone, 40 g Celestone chronodose, 1 mL, 5.7 mg/mL* (study from Australia) Methylprednisolone, 40 mg

There are no dose–responses studies.  
\*Other studies on greater occipital nerve block did not state the corticosteroid used or did not state the dose of cortivazol.  
†In the USA, betamethasone (Celestone Soluspan; Schering-Plough, Kenilworth, New Jersey), 6 mg/mL, contains 3 mg/mL betamethasone sodium phosphate (short-acting component) and 3 mg/mL betamethasone acetate (long-acting component). Each mL of celestone chronodose contains betamethasone 5.7 mg, as betamethasone sodium phosphate (3.9 mg) and betamethasone acetate (3 mg).

Intercostal and paravertebral nerve blocks can be performed using landmark techniques, nerve stimulation, fluoroscopy, or US.<sup>93 100</sup> Optimal imaging for intercostal and paravertebral nerve blocks and comparative efficacy of these procedures continues to be a subject of debate. A retrospective review of 39 intercostal nerve blocks (12 US-guided and 27 fluoroscopy-guided) blocks showed similar efficacy measured by patient-reported pain scores and duration of pain relief.<sup>101</sup> Dynamic US was recommended for a better understanding of functional anatomy in patients with slipped rib syndrome.<sup>93</sup> Corticosteroids have been added to the injectate to theoretically prolong the normally expected short-term relief from LA.<sup>102</sup> An intercostal injection of bupivacaine-dexamethasone microspheres in sheep produced effective chest wall analgesia of several days' duration.<sup>103</sup> The benefit of adding corticosteroids, however, was not measured in this or many other older studies.

The number of blocks required for clinically meaningful outcomes in herpes zoster is not well defined. A single-blinded RCT on compared twice weekly versus three times weekly paravertebral injections of 25 mg bupivacaine plus 8 mg dexamethasone in patients with acute herpes zoster.<sup>18 104</sup> Both groups experienced benefit, but there was no added benefit from repeating the blocks more than twice.<sup>104</sup> Contrary to these findings, a repetitive paravertebral block with LA and corticosteroids (every 48 hours for 1 week) plus standard treatment with acyclovir and analgesics significantly reduced the incidence

of postherpetic neuralgia compared with standard treatment alone.<sup>105</sup>

ADVERSE EVENTS

Other than pneumothorax, both intercostal and paravertebral nerve blocks are low-risk interventional procedures. In one retrospective study, 13 cases of intercostal, paravertebral blocks, costotransverse or erector spinae block resulted in cancer pain relief without any reported complications.<sup>106</sup> However, potential for corticosteroid-related systemic complications must be considered.

A spinal cord injury resulting from fluoroscopic-guided intercostal blocks with phenol injection at the T7 through T9 levels occurred in a patient with a history of multiple previous intercostal blocks for chronic mid-thoracic and abdominal pain without sequelae.<sup>95</sup> Imaging showed edema in the central spinal cord from T1 to L1. Despite the absence of intravascular uptake of the contrast or reported tracking into the paravertebral or epidural space, it is likely that intravascular uptake, possibly arterial, may have occurred during the injection. This case raises a concern about using particulate corticosteroids for intercostal or paravertebral block at the mid-thoracic level.

Statements and recommendations are presented in box 3.

TRANSVERSE ABDOMINIS, ILIOINGUINAL/ILIOHYPOGASTRIC NERVE BLOCKS FOR CHRONIC PAIN  
Introduction

Fascial plane blocks utilized perioperatively yielded improved outcomes in the era of enhanced recovery pathways.<sup>107</sup> Theoretically, the utilization of transverse abdominis plane (TAP) block and ilioinguinal/iliohypogastric nerve blocks for chronic painful states is a logical progression from their perioperative use. However, there is a dearth of literature on the use of these techniques for *chronic* pain.

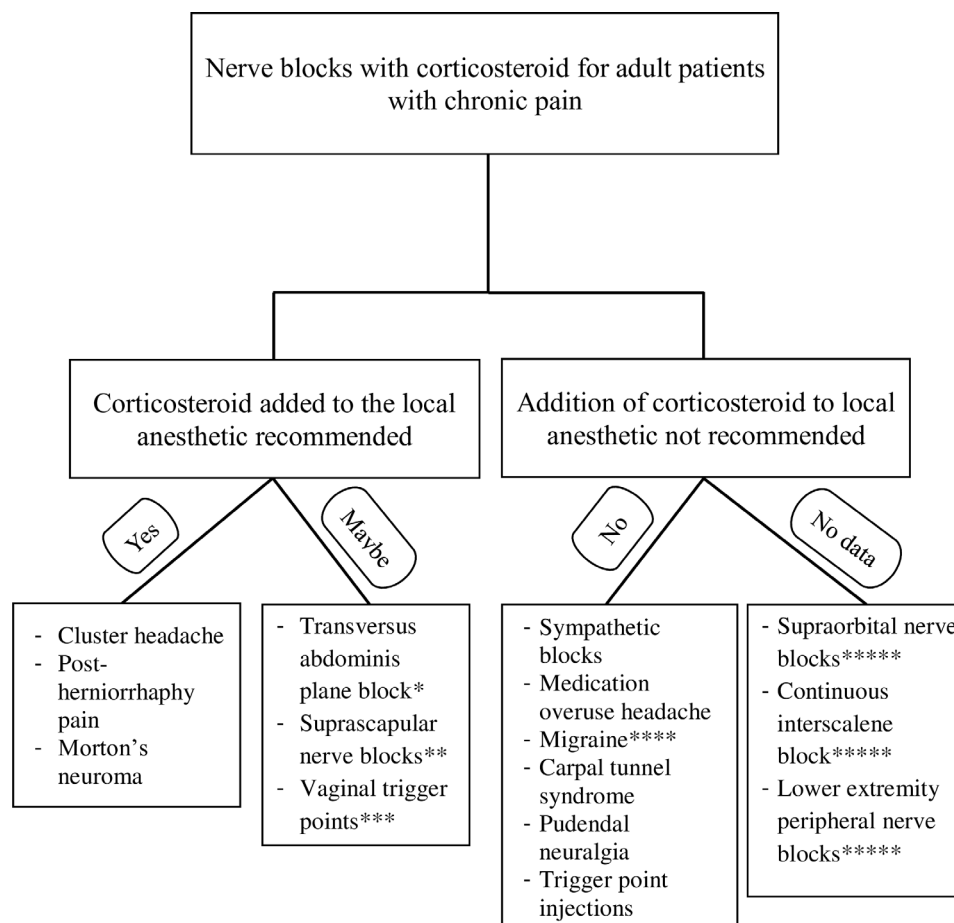
TAP BLOCK

This procedure is performed for analgesia in the abdominal area including colorectal issues, postherniorrhaphy and post-cesarean section pain. Intuitively, clinicians perform these blocks under US guidance to confirm spread of the injectate in the correct fascial plane. A perioperative prospective blinded study had to be stopped prematurely because of low success rate (24% correct placement) and unacceptably high level of peritoneal needle placements (18%) in the landmark technique.<sup>108</sup> US guidance is especially helpful in patients with obesity, reduced muscle mass (risk of organ penetration), or close proximity to sensitive tissues.

One study showed the benefit of corticosteroid and LA TAP blocks under US guidance for the chronic abdominal pain syndrome.<sup>109</sup> The authors presented two cases of analgesic benefit for chronic anterior cutaneous nerve entrapment syndrome. Another study evaluated the efficacy of LA and steroid TAP blocks in 54 patients with chronic pancreatitis pain.<sup>110</sup> The TAP block produced clinically significant relief up to 6 months in 62% (13 of 21) of patients with myofascial pain. For patients with visceral pain, TAP block yielded relief of 2–3 weeks duration in 35% (6 of 17) of patients. There are no clinical studies comparing landmark versus US-guided technique.

TAP BLOCKS WITH CORTICOSTEROIDS

Abd-Elsayed *et al* highlighted the role of TAP blocks for the treatment of chronic abdominal pain in two retrospective chart



**Figure 2** Decision tree showing the effect of additional corticosteroid to the local anesthetic in specific nerve blocks and chronic pain syndromes.

\*Two retrospective reviews (30 and 92 patients) showed benefit of transversus abdominis plane block for chronic abdominal pain, but no study compared local anesthetic with and without corticosteroid. \*\*Two retrospective reviews (18 and 71 patients) showed benefit of suprascapular nerve blocks for shoulder pain, but no study compared local anesthetic with and without corticosteroid. \*\*\*Retrospective review of 27 postpartum women showed benefit of vaginal trigger point injections with local anesthetic and corticosteroid, but no study compared local anesthetic with and without steroid. \*\*\*\*Prospective observational studies, but not randomized trials, showed benefit of adding corticosteroid. \*\*\*\*\*No data on effect of addition of corticosteroid.

reviews.<sup>111 112</sup> In one study, 30 patients with chronic abdominal pain received bupivacaine and triamcinolone via a US-guided block after the failure of other forms of pain management. Nearly 80% of patients had at least 50% improvement for 84 days after the blocks. Additionally, membrane stabilizer use decreased in patients after the procedure.<sup>112</sup> In the other study, 92 patients with chronic abdominal pain received 163 TAP blocks consisting of LA and corticosteroids by a US-guided approach. Each patient received anywhere from 1 to 10 blocks with resulting pain relief after 82% of these procedures, with an average duration of improvement of 108 days.<sup>111</sup> The authors suggest that this technique can yield relief of somatosensory-refractory abdominal pain.

In patients with anterior cutaneous nerve entrapment syndrome, a single-blinded RCT showed addition of methylprednisolone to lidocaine injection into the point of maximal abdominal pain did not improve the results. The decrease in pain at 6-week and 12-week follow-up in both groups was not significantly different.<sup>113</sup>

Statements and recommendations are presented in [box 3](#).

There is insufficient evidence to formulate a statement or recommendation regarding the role of corticosteroids in TAP blocks for chronic pain.

### ILIOINGUINAL/ILIOHYPOGASTRIC NERVE BLOCKS

The use of US has a theoretical benefit in targeting abdominal neural landmarks based on a cadaveric study,<sup>114</sup> which noted a 95% success rate in US guidance for the ilioinguinal and iliohypogastric nerves. In this study, the authors noted that they visualized and targeted the nerve 5 cm cranial and posterior to the anterior superior iliac spine and that it may be difficult to reach the ilioinguinal nerve with the described blind technique.<sup>114</sup> However, a retrospective review compared US-guided (n=36) versus landmark (n=20) technique in patients with chronic postherniorrhaphy pain<sup>115</sup> and found no statistically significant difference in terms of pain relief. No complications were noted with either technique.

Another study compared outcomes in patients receiving US-guided ilioinguinal/iliohypogastric nerve blocks versus nerve stimulator-guided blocks in patients with chronic abdominal pain after inguinal hernia surgery.<sup>116</sup> After US-guided blocks, patients had a higher VAS score with activity and more anxiety and depression compared with patients in whom similar blocks were performed with nerve stimulator guidance. The criticisms of this study include its retrospective nature; nerve stimulators were used prior to 2009 compared with US guidance after 2009,

and variability in patient follow-up between studied groups (average of 38 months for the nerve stimulator group and 13 months for the US group). Additionally, anxiety and depression most likely reflect the patients' response to pain irrespective of the technique.<sup>116</sup>

### ROLE OF ADDED CORTICOSTEROIDS IN POSTHERNIORRHAPHY PAIN

A scoping review of the literature evaluated the use of corticosteroid injectate for chronic postherniorrhaphy pain and discussed four publications including three prospective case series and one retrospective cohort study in patients with chronic postsurgical pain.<sup>117</sup> Methylprednisolone, triamcinolone, and cortivazol were added to the LA. Two studies used landmarks, one with CT, while another used US and nerve stimulator. All studies demonstrated sustained analgesic benefit with the addition of corticosteroid therapy. The duration of "good response" in the reviewed studies was 51 months, mean duration of 1.6 months, and 21 months; one study did not provide their follow-up results.<sup>117</sup> The good results were in spite of the non-blockade of the genitofemoral nerve, also a mediator to the sensation of postherniorrhaphy pain, in two of the studies. In this review, the four studies on postherniorrhaphy pain employed LA and corticosteroid making it difficult to assess any added benefit of the corticosteroid. In a fifth study, the injections were done preoperatively.<sup>117</sup> The investigators noted no benefit of adding corticosteroid to the LA in terms of quality and duration of pain after inguinal hernia.

Statements and recommendations are presented in [box 3](#).

### CERVICAL AND UPPER EXTREMITY NERVE BLOCKS FOR CHRONIC PAIN

Chronic pain in the upper extremity usually involves the shoulder, elbow, arm, forearm, or the entire upper extremity. Chronic shoulder pain is mostly from adhesive capsulitis, subacromial bursitis, stroke (hemiplegic shoulder pain),<sup>118</sup> or from rotator cuff tears.<sup>119</sup> It may present as a chronic painful shoulder syndrome with no obvious pathology.<sup>120 121</sup> Chronic lateral and medial epicondylitis results in chronic elbow pain.<sup>122 123</sup> *Shoulder and elbow pain are discussed in the guideline on joint injections.* Chronic ulnar neuropathy causes forearm pain while CRPS, chemical burn, and peripheral arterial occlusive disease all cause upper extremity pain.<sup>124-126</sup>

US guidance was used in posterior antebrachial cutaneous nerve,<sup>122</sup> phrenic nerve,<sup>127</sup> suprascapular nerve block,<sup>120 121 128</sup> and ulnar nerve blocks.<sup>129</sup> An RCT compared US guided with landmark-guided suprascapular nerve block and noted no difference between the two techniques, and both resulted in significant pain relief.<sup>120</sup>

Studies of upper extremity nerve blocks have been mostly case reports or case series, with no RCT involving a reasonable sample size. One double-blind, placebo-controlled pilot RCT of 12 patients showed better results with ropivacaine compared with placebo in phrenic nerve blocks.<sup>127</sup>

Most of the studies employed LA only, and all showed varying degrees of relief and duration. One publication showed sustained relief for 42 days after a continuous interscalene block for 45 days.<sup>130</sup> Three case series involved corticosteroid added to LA nerve block. Triamcinolone 20 mg was added to 0.5% bupivacaine in suprascapular nerve block, all 18 patients had relief with improved range of motion of their shoulders.<sup>128</sup> Another suprascapular nerve block study used 40 mg triamcinolone and 0.25% levobupivacaine; relief was noted at 72 hours,

1 month, 3 months, and 6 months in 81%, 90%, 76%, and 62% of 71 patients, respectively.<sup>121</sup> A third study of 15 patients noted pain relief for an average of 15 hours (range: 2–48 hours) after posterior antebrachial cutaneous nerve block using LA with or without corticosteroid.<sup>122</sup> There are no RCTs evaluating the beneficial effect of additional corticosteroid to the LA.

### CARPAL TUNNEL

Locally deposited corticosteroid injections into the carpal tunnel to treat carpal tunnel syndrome (CTS) have been utilized for the treatment of pain associated with CTS for several years.<sup>131</sup> A Cochrane Review in 2007 concluded that use of local injection of corticosteroid in the treatment of CTS did not demonstrate any improvement in pain or function after 1 month as compared with placebo.<sup>132</sup> A more recent RCT showed superiority of 5% dextrose in treatment of the pain and in terms of electrophysiological improvement from CTS as compared with corticosteroids.<sup>133</sup> Kamel *et al* showed that local injection of insulin for mild-to-moderate CTS had equal efficacy to corticosteroid in patients with diabetes mellitus type 2 in terms of functional assessments, ultrasonographic visualization of the median nerve, and electrophysiological parameters.<sup>134</sup>

Several studies demonstrated superiority of US visualization versus landmark-based injections. Studies showed greater improvements in the Boston Carpal Tunnel Questionnaire Severity Scale (a scale that addresses pain, numbness, tingling, and difficulty with fine motor skills) with US compared with palpation technique, with greater decrease in the flattening ratio and cross-sectional area of the median nerve with an in-plane, US-guided ulnar approach as opposed to landmark-based injection or out-of-plane US injection.<sup>135 136</sup> Another study showed US guidance to be superior in monofilament testing and sensory nerve conduction studies, but that there was no difference with clinical symptoms and signs, physical function, and most electrodiagnostic parameters when compared with landmark-based injections.<sup>137</sup> The lack of difference between landmark-based injections and US injections for CTS with steroid in terms of pain or function was noted in another study.<sup>138</sup>

### SUMMARY

Existing literature evaluating upper extremity PNBs for chronic pain consists mostly of case reports or series. A salutary effect of US in suprascapular nerve block was not shown.<sup>120</sup> However, US should be considered in nerve blocks where visualization of the nerve is vital, for example, forearm ulnar nerve block<sup>129</sup> and posterior antebrachial cutaneous nerve block.<sup>122</sup> Given variable data quality, SRs were generated for CTS only in cases where evidence is robust ([box 4](#)).

### LOWER EXTREMITY PNBs FOR CHRONIC PAIN

PNBs in the lower extremity have been performed with a variety of techniques, such as landmark guided, electrical stimulation guided, and US guided.<sup>139</sup> Because it allows direct visualization, US was intuitively used by practitioners. Analysis of 34 studies up to 2016 showed that the use of US showed shorter performance time, shorter onset time, and increased complete sensory block.<sup>139</sup> No study showed US to be inferior to nerve stimulation. However, nerve stimulation can be used to confirm nerve location, especially when there are anatomical variations, the target nerve is deep, and in patients with obesity.<sup>139 140</sup>

The use of corticosteroids as an adjunctive agent during PNBs for pain of lower extremity is not well studied. Case reports and case series demonstrated that corticosteroids could be used



safely in PNBs of the lateral femoral cutaneous nerve, the inferior cluneal nerve, and the femoral nerve; however, no data compared utilizing steroids with LA alone.<sup>141–148</sup>

Blockade of the pudendal nerve with corticosteroids has been evaluated in comparison to LA alone in an RCT. Labat *et al* noted that 3 months post procedure, 12% of patients in the LA only arm were responders versus 14% in the combined arm. This difference was not statistically significant ( $p=0.62$ ).<sup>149</sup> Importantly, this study utilized CT guidance to identify the pudendal nerve, and there was no difference in complications between the study groups.<sup>149</sup>

## MORTON NEUROMA

Morton neuroma is an entrapment neuropathy that occurs between the digits of the foot, most commonly the third plantar digital nerve.<sup>150 151</sup> A randomized trial comparing US-guided to landmark-guided Morton neuroma injections demonstrated a statistically significant difference in favor of US guidance in terms of pain relief at 45 days, 2 months, and 3 months follow-up.<sup>152</sup> A 2020 systematic review assessed five studies (three RCTs, one comparative study, and one prospective cohort study) that evaluated the use of corticosteroids for the treatment of Morton's neuroma pain.<sup>153</sup> Compared with other treatments (alcohol injection, extracorporeal shock-wave, capsaicin, cryoablation, RFA), corticosteroid injection showed a statistically significant reduction of pain scores. Pooled data demonstrated that 50% of patients were pain free at 1 year post injection.<sup>153</sup> Minimal complications were reported. Additionally, two studies combined corticosteroid with LA,<sup>154 155</sup> while one study showed the combination of corticosteroid and lidocaine more effective than the corticosteroid alone.<sup>156</sup>

Statements and recommendations are presented in [box 4](#).

## TRIGGER POINT INJECTIONS

### Background

Myofascial trigger points (TrPs) are identified by areas of focal hypertonicity located within a band of taut muscle. These bands may be caused by acute trauma or repetitive microtrauma<sup>157</sup> associated with acute or chronic pain and may be debilitating in patients' performance of daily activities. TrPs can occur in any area of skeletal muscle; however, most are commonly found in the head, neck, shoulders, back, and buttocks regions.<sup>158</sup>

The pathophysiology of TrPs is still unknown; the prevailing theory is the "integrated hypothesis" which states that motor end plate dysfunction and localized tissue ischemia prevent normal function at the postsynaptic junction. Overactivity at the motor end plate leads to an abundance of acetylcholine and calcium release, which in turn, causes sustained contraction of skeletal muscle. Constant contraction eventually depletes available ATP and contributes to localized hypoxia with muscle dysfunction.<sup>157 159 160</sup> Evidence for this hypothesis is supported by increased markers of inflammation such as serotonin, calcitonin gene-related peptide, bradykinin, interleukin, and substance P in the area surrounding the TrP.<sup>160–162</sup>

The diagnosis of TrPs is often made clinically; however, more specific diagnostic modalities such as US elastography, magnetic resonance elastography, and electromyography (EMG) are available. TrP produces localized electrical activity within the muscle fiber, which can be quantified via EMG—a modality with high operating cost. With US, TrPs are displayed as focal, hypoechoic regions on B-mode US within a muscle.<sup>163–165</sup> Other authors noted that TrPs appear as hyperechoic on the US.<sup>166 167</sup> A study comparing physical examination findings with US showed that

both modalities produced almost identical results, suggesting that US may make diagnosis of treatment areas more objective.<sup>164</sup>

Treatment for TrPs involves first-line conservative therapies such as non-steroidal anti-inflammatory drugs (NSAIDs), ethyl chloride spray, stretch, and rest.<sup>157</sup> Depending on case severity, more invasive management may be indicated. Intramuscular corticosteroid/LA TPIs are regarded as the most common procedure for symptom resolution. While evidence supports the use of LA for TPI therapy, little research supports adding corticosteroids to TPIs.

### Techniques—dry needling

TrP dry needling is a technique employed by acupuncturists and other healthcare professionals wherein solid filiform needles are used to disrupt the TrP and relax the muscle fibers.<sup>168</sup> Patients often experience immediate pain relief after treatment. Repeat therapy may reduce pain over several months.<sup>168</sup> Most papers demonstrated some benefit using dry needling monotherapy for TPIs; however, there are not enough high-quality, long-term large-scale studies to draw any clear conclusions about its efficacy. The optimal frequency, duration, and intensity are yet to be determined.<sup>169</sup> A recent review and meta-analysis concluded, with low evidence, that TPIs with lidocaine were superior to dry needling in terms of pain relief.<sup>170</sup> However, TPIs did not provide better results in terms of pain-related disability, range of movement, or depression compared with dry needling. In this review, the injectates in the studies were either lidocaine, botulinum toxin A injection or flurbiprofen.<sup>170</sup>

## TRIGGER POINT INJECTIONS

TPIs may be performed without imaging guidance by manually palpating to identify the target, inserting the needle to elicit a twitch response, and administering injectate.<sup>157 171</sup> On US, the skin is hyperechoic, adipose tissue has mixed echogenicity and muscle is hyperechoic with marbled appearance.<sup>172</sup> As previously noted, the TrP may be visualized as focal, hypoechoic or hyperechoic regions on US.<sup>163–167</sup> Use of US helps in the avoidance of neurovascular structures or viscera,<sup>172 173</sup> confirms LA infiltration between fascial planes,<sup>174</sup> and can visually demonstrate the muscle twitch response, especially in deep or small-target muscles.<sup>175</sup>

For trapezius US-guided TPIs, it has been recommended to identify increased shear wave speed within painful areas of the trapezius muscle.<sup>176</sup> Also recommended is the use of a posterior in-plane approach of the muscle belly of the upper trapezius to avoid the superficial and deep branches of the transverse cervical artery and the spinal accessory nerve.<sup>177</sup> For the thin serratus anterior muscle, the TrPs are marked over the midaxillary line.<sup>178</sup> Using the transverse plane, the US probe is superiorly angled to bring the intercostal space, the pleura, and the rib with the serratus anterior muscle insertion into view.<sup>178</sup>

Studies have shown US-guided TPIs to have improved accuracy compared with landmark-guided injections, especially when targeting deeper anatomic structures.<sup>179–181</sup> Favorable pain relief outcomes were noted with US-guided injections compared with blind injections.<sup>176 182</sup> In a randomized controlled study, the pain scores, neck disability index, and shoulder pain disability index were significantly better in the US-guided group.<sup>176</sup> In an emergency department setting, US-guided TPIs have also been shown to improve short-term pain scores and reduce rescue medications compared with multimodal oral analgesic therapy.<sup>183</sup> Similar superiority was demonstrated in a small study showing landmark technique TPIs are superior to intravenous NSAIDs.<sup>184</sup>

## STUDIES ON TPIS: LA ALONE, LA AND CORTICOSTEROID

The therapeutic use of LA within the context of TPis has been shown to reduce postinjection soreness. A concern with LAs is myotoxicity. Although in vivo studies are lacking, evidence suggests that LAs are associated with reversible muscle necrosis,<sup>185</sup> greater risk of necrosis occurring with use of bupivacaine, higher concentration of LA, and prolonged exposure.<sup>186–187</sup> The mechanisms include aberrations of cytoplasmic calcium homeostasis by the sarcoplasmic reticulum Ca ATPase. The time to recovery in humans can be 4 days although the typical time course for regeneration is 3–4 weeks.<sup>187</sup> Intramuscular injection of bupivacaine is more painful than ropivacaine, potentially due to its increased myotoxic potential given their similar pH levels, and the addition of a steroid increases the pain response.<sup>188</sup> There are no studies that compare the degree and duration of benefit from various LAs.

## LAs with steroids

Corticosteroids have been used for TPis based on their known anti-inflammatory properties, but no evidence supports corticosteroid use in TPis. In patients with low back pain, a prospective, double-blind RCT noted equal efficacy of lidocaine with and without triamcinolone, acupuncture, and vaporized coolant spray with acupressure.<sup>189</sup> An RCT showed similar efficacy in patients with headache from myofascial pain syndrome with all the following injections: dry needling, TPI with lidocaine alone, TPI with lidocaine and dexamethasone.<sup>190</sup> Several studies concluded that corticosteroids have a minimal, if any, benefit on treatment success.<sup>190–192</sup> The studies were heterogeneous; comparing different substances, injection versus dry needling or vapocoolant spray.<sup>190–192</sup> In spite of heterogeneity, the injectate was not noted to be a critical factor.<sup>189</sup> While one study noted less postinjection sensitivity with lidocaine and steroid combination,<sup>190</sup> this minor benefit does not justify the routine use of corticosteroid in TPis (see box 5).

A unique application of corticosteroid injection is seen in vaginal TPis, in which a mepivacaine/corticosteroid combination has been shown to significantly decrease perineal pain in postpartum women.<sup>193</sup> This retrospective case review concluded that LAs and corticosteroids provide a safe and effective method for managing moderate-to-severe vaginal pain.

## ADVERSE EFFECTS OF TPIS

Complications from TPis are related to a variety of issues related to needle placement and the type of injectate. Potential adverse effects related to needle placement include pain, bruising, superficial infection, vascular injury, and visceral injury.<sup>171 194–197</sup> Complications related to injectate include allergic reaction, LA systemic toxicity, hypokalemia, and atrophy of subcutaneous tissues and skin. While generally considered to be a very low-risk procedure, severe complications include intramuscular hematoma formation,<sup>198</sup> spinal cord injury,<sup>199</sup> pneumothorax,<sup>200</sup> severe hypokalemic paralysis,<sup>201 202</sup> pneumocephalus, necrotizing mediastinitis, and deep tissue abscess requiring drain placement<sup>203</sup> have been described in case reports.

Visualization of the pleura with US guidance during cervicothoracic musculature injections has been described as a method to reduce the risk of pneumothorax.<sup>172 177 204</sup> There was no bleeding, bruising, or other adverse events reported in a retrospective study examining patients who underwent US-guided TPI for abdominal myofascial pain syndrome.<sup>205</sup>

## SUMMARY

US improves the safety of TPis especially in muscles that are deep or near sensitive tissues (eg, serratus anterior). Corticosteroids are often used in TPis; however, there is no evidence showing benefit, and their use may increase risk of infection in addition to other systemic effects of steroid exposure.

Statements and recommendations are presented in box 5.

## PIRIFORMIS SYNDROME

Piriformis injection for piriformis syndrome may be considered a TPI if the injection is made into the muscle, without sciatic nerve block. Piriformis syndrome is caused by trauma to the pelvis or buttock, hypertrophy of the piriformis muscle, anatomic abnormalities of the piriformis muscle or the sciatic nerve, differences in leg lengths, or piriformis myositis.<sup>206</sup> The inflamed, enlarged, or stretched piriformis may compress the sciatic nerve between the muscle. Characterized by buttock pain, the pain may radiate to the ipsilateral posterior thigh and leg, similar to a radicular pain except it originates in the buttock. Differential diagnosis includes a herniated disc or spinal stenosis, facet syndrome, sacroiliac joint dysfunction, myofascial pain syndrome and conditions irritating the sciatic nerve. Diagnosis is made after a thorough medical history and physical examination.

Piriformis syndrome may be treated by injection of corticosteroid and LA into the muscle. Some clinicians also elect to inject perisciatic corticosteroid, preferably without LA to avoid motor weakness, a method preferentially targeted to patients with radiating pain along the sciatic distribution.<sup>206</sup> A randomized double-blinded study showed similar benefits after US-guided piriformis injection with lidocaine and lidocaine with betamethasone injection.<sup>191</sup>

Recommendations regarding piriformis injections were not formulated in this manuscript due to concerns with published studies. These include technique (in one study, the figure showed the gluteus muscle rather than piriformis); insufficient studies examining placement of injectate (piriformis injection only vs piriformis and perisciatic injections); different injectates (LA, steroid, botulinum toxin); and limited studies examining the role of corticosteroid or dose–response studies. Additionally, classification of a piriformis injection as a TPI may be disputed.

## LIMITATIONS OF THE GUIDELINE AND BARRIERS TO ITS IMPLEMENTATION

Creation of a user-friendly document in the patient's record that collates corticosteroid injection use from all sources in a particular period or simple documentation of the patient's steroid medications would aid in the implementation of this guideline but may pose challenges. Although documentation can be time consuming, and the patient may not be aware of the corticosteroids (s)he had taken, this record would be beneficial for patient safety.

Limitations of our guideline include the heterogeneity and dosage of the corticosteroids used in the studies, non-inclusion of stakeholders, for example, patient advocacy groups and incomplete adherence to the Appraisal of Guidelines, Research and Evaluation (AGREE II) recommendations.<sup>207 208</sup> However, it should be noted that other guidelines may not be completely in alignment with these recommendations,<sup>209</sup> and like other guidelines, AGREE II recommendations are not mandates but rather, suggestions. In addition, we identify many areas in which there is insufficient evidence to characterize the benefit or safety of corticosteroids and it is important that high-quality clinical research address these deficiencies to support evidence-based practice.

## SUMMARY

In this PG, we discuss injections for sympathetic blocks, PNBs, and TPIs for adult patients with chronic pain, and describe relevant imaging guidance for injection techniques and the salutary role of corticosteroids in the injectate. The commonly used corticosteroid doses in these nerve blocks and chronic pain conditions are listed in [table 2](#).

The safety of some procedures, including stellate blocks, lower extremity PNBs, and some TrP injections, is improved by imaging guidance. For cluster headaches, the addition of corticosteroid to the LA is beneficial but not in other types of headaches. Corticosteroids provide additional benefit in postherniorrhaphy pain and Morton's neuroma and may impart some benefit in TAP blocks and supracapular nerve blocks and vaginal TrPs ([figure 2](#)). Our guidelines are intended to facilitate clinicians in making evidence-based decisions in their practice to decrease the potential for adverse events and mitigate healthcare costs.

## Author affiliations

- <sup>1</sup>Anesthesiology, Feinberg School of Medicine, Chicago, Illinois, USA
- <sup>2</sup>Department of Anesthesia, University of Chicago Medical Center, Chicago, Illinois, USA
- <sup>3</sup>Anesthesiology, Clement Zablocki VA Medical Center/Medical College of Wisconsin, Milwaukee, Wisconsin, USA
- <sup>4</sup>Anesthesiology, University of Kansas Medical Center, Kansas City, Kansas, USA
- <sup>5</sup>University of California Irvine, Orange, California, USA
- <sup>6</sup>Pain Medicine, Western Reserve Hospital, Cuyahoga Falls, Ohio, USA
- <sup>7</sup>Orthopaedics and PM&R, Medical University of South Carolina, Charleston, South Carolina, USA
- <sup>8</sup>Pain Medicine, MD Anderson Cancer Center, Houston, Texas, USA
- <sup>9</sup>Anesthesiology, Loma Linda University Medical Center, Loma Linda, California, USA
- <sup>10</sup>University of Wisconsin Madison School of Medicine and Public Health, Madison, Wisconsin, USA
- <sup>11</sup>Anesthesiology and Critical Care Medicine, Johns Hopkins Medicine, Baltimore, Maryland, USA
- <sup>12</sup>Anesthesiology, University of Texas Health Science Center at San Antonio, San Antonio, Texas, USA
- <sup>13</sup>Endocrinology, Walter Reed National Military Medical Center, Bethesda, Maryland, USA
- <sup>14</sup>Pain Medicine, Mayo Clinic, Jacksonville, Florida, USA
- <sup>15</sup>Anesthesiology, Naval Medical Center San Diego, San Diego, California, USA
- <sup>16</sup>Orthopedic Surgery, LSUHSC, New Orleans, Louisiana, USA
- <sup>17</sup>PM&R, Vanderbilt University Medical Center, Nashville, Tennessee, USA
- <sup>18</sup>PM&R, Cleveland Clinic, Cleveland, Ohio, USA
- <sup>19</sup>American Society of Regional Anesthesia and Pain Medicine, Pittsburgh, Pennsylvania, USA
- <sup>20</sup>Anesthesiology, The University of Texas Health Science Center at San Antonio, San Antonio, Texas, USA
- <sup>21</sup>Medicine (Rheumatology), UCLA, Los Angeles, California, USA
- <sup>22</sup>Department of Radiology, Massachusetts General Hospital, Boston, Massachusetts, USA
- <sup>23</sup>University of Pittsburgh Health Sciences, Pittsburgh, Pennsylvania, USA
- <sup>24</sup>University of Louisville Health Sciences Center, Louisville, Kentucky, USA
- <sup>25</sup>Pain Diagnostics and Interventional Care, Sewickley, Pennsylvania, USA
- <sup>26</sup>Anesthesia, Division of Pain Medicine, University Hospitals Cleveland Medical Center, Cleveland, Ohio, USA
- <sup>27</sup>Anesthesiology, Walter Reed National Military Medical Center, Bethesda, Maryland, USA
- <sup>28</sup>Radiology, Mayo Clinic, Rochester, Minnesota, USA
- <sup>29</sup>Department of Anesthesiology and Perioperative Medicine, University of California Irvine, Irvine, California, USA
- <sup>30</sup>Department of Aerospace Medicine, Exploration Medical Capability, Johnson Space Center
- <sup>31</sup>Anesthesia, McMaster University, Hamilton, Ontario, Canada

**Correction notice** This article has been corrected since it published Online First. The acknowledgement statement has been amended.

**X** Shalini Shah @ShaliniShahMD, Tina L Doshi @dr\_tinadoshi, Maxim S Eckmann @eckmann\_max, Samer Narouze @NarouzeMD, Ariana M Nelson @ANels\_MD and Harsha Shanthanna @harshamd5

**Acknowledgements** Copyediting and formatting were performed by Emma Hitt Nichols, PhD, on behalf of Nascent Medical, LLC. The authors would like to thank Ms

Elizabeth Smith, of ASRA, for coordinating this project and outreach to participating organizations. The Clinical Practice Guidelines of the American Academy of Physical Medicine and Rehabilitation provided a useful critique of the initial manuscript. Brian D Sites, MD, MS recommended the figure on decision tree.

**Contributors** All the authors were involved in the Delphi process, approval of the statements and recommendations, and approval of the manuscript. The primary author, HTB, guarantees the contributorship statement.

**Funding** The authors have not declared a specific grant for this research from any funding agency in the public, commercial or not-for-profit sectors.

**Competing interests** HTB, MD: NIH NIAMS P30AR072579. AC, MD: Research Funding: RM1NS128956-01A1; Consultant: Swing Therapeutics, Scilex Pharmaceuticals. SS, MD: Consultant: SPR Therapeutics, Allergan, Inc. DS, MD: Advisory Board, Funded research: Scilex; Speaker: AbbVie. AN, MD: Speaker: Averitas Pharmaceuticals; Research: Saol Therapeutics. AA-E, MD: Consultant: Curonix. TD, MD: Research support: Biohaven, NIH; Consultant: Guidepoint Global; Speaker honorarium: Remedy Health Media. MSE, MD: Funded research: SPR Therapeutics; Consultant: Avanos, Abbott. TH, MD: Acella: Advisory board, speaker: Acella. CH, MD: Research grant: Nevro, Inc. CP, MD: Consulting: Mainstay Medical; Royalties, UpToDate. BS, MD: Consultant: State Farm, Caelon. AS, MD: NIH R34AR080279. MM, MD: Consultant: Juris Medicus. JAH, MD: Grants: Neiman Health Policy Institute (there is no number associated with this foundation grant; Consulting (last 12 months): Medtronic, Relievant, Persica; DMC Chair: Balt, Rapid Medical, Arsenal. AW, MD: Investigator-initiated grant, Goodblends, PA. DAP, MD: Consulting: Avanos, Boston Scientific, Medtronic, Nevro, and SI Bone. Research support: Avanos, Boston Scientific, Medtronic, Nevro, Stimpson, Abbott. SPC, MD: Consulting (past 2 years): Avanos, Scilex, SPR, SWORD, Releviate (ended), Clearing (ended), Persica (inactive); Research funds paid to institution: Scilex, Avanos. TM, MD: Consultant, Interventional Analgesix. The remaining authors declare no competing interests.

**Patient consent for publication** Not applicable.

**Ethics approval** Not applicable.

**Provenance and peer review** Not commissioned; externally peer reviewed.

**Data availability statement** All data relevant to the study are included in the article or uploaded as supplementary information.

**Supplemental material** This content has been supplied by the author(s). It has not been vetted by BMJ Publishing Group Limited (BMJ) and may not have been peer-reviewed. Any opinions or recommendations discussed are solely those of the author(s) and are not endorsed by BMJ. BMJ disclaims all liability and responsibility arising from any reliance placed on the content. Where the content includes any translated material, BMJ does not warrant the accuracy and reliability of the translations (including but not limited to local regulations, clinical guidelines, terminology, drug names and drug dosages), and is not responsible for any error and/or omissions arising from translation and adaptation or otherwise.

## ORCID iDs

Honorio T Benzon <http://orcid.org/0000-0003-1376-8003>  
 Dalia Elmofly <http://orcid.org/0000-0001-9937-3226>  
 Hariharan Shankar <http://orcid.org/0000-0002-1567-3887>  
 Andrea L Chadwick <http://orcid.org/0000-0002-0570-9997>  
 Shalini Shah <http://orcid.org/0000-0001-5200-225X>  
 Ameet S Nagpal <http://orcid.org/0000-0001-5642-3465>  
 Salahadin Abdi <http://orcid.org/0000-0002-3892-9208>  
 Christian Rafla <http://orcid.org/0000-0002-7932-1055>  
 Tina L Doshi <http://orcid.org/0000-0001-5011-3298>  
 Thanh D Hoang <http://orcid.org/0000-0001-7437-5604>  
 Christine Hunt <http://orcid.org/0000-0002-0507-7889>  
 Carlos A Pino <http://orcid.org/0000-0002-7560-8403>  
 Byron J Schneider <http://orcid.org/0000-0002-9237-3108>  
 Alison Stout <http://orcid.org/0009-0000-5651-6602>  
 Angela Stengel <http://orcid.org/0000-0002-7701-924X>  
 John D FitzGerald <http://orcid.org/0000-0002-8419-7538>  
 Ajay D Wasan <http://orcid.org/0000-0002-6394-6077>  
 David Anthony Provenzano <http://orcid.org/0000-0002-2147-3523>  
 Samer Narouze <http://orcid.org/0000-0003-1849-1402>  
 Steven P Cohen <http://orcid.org/0000-0001-5928-2127>  
 Ariana M Nelson <http://orcid.org/0000-0003-1575-1635>  
 Harsha Shanthanna <http://orcid.org/0000-0002-4105-4465>

## REFERENCES

- 1 Vlassakou KV, Narang S, Kissin I. Local anesthetic blockade of peripheral nerves for treatment of neuralgias: systematic analysis. *Anesth Analg* 2011;112:1487–93.
- 2 Afridi SK, Shields KG, Bhola R, et al. Greater occipital nerve injection in primary headache syndromes—prolonged effects from a single injection. *Pain* 2006;122:126–9.



- 3 Barnes PJ, Adcock I, Spedding M, *et al.* Anti-inflammatory actions of steroids: molecular mechanisms. *Trends Pharmacol Sci* 1993;14:436–41.
- 4 Devor M, Govrin-Lippmann R, Raber P. Corticosteroids suppress ectopic neural discharge originating in experimental neuromas. *Pain* 1985;22:127–37.
- 5 Johansson A, Bennett GJ. Effect of local methylprednisolone on pain in a nerve injury model. A pilot study. *Reg Anesth* 1997;22:59–65.
- 6 Johansson A, Hao J, Sjölund B. Local corticosteroid application blocks transmission in normal nociceptive C-fibres. *Acta Anaesthesiol Scand* 1990;34:335–8.
- 7 Harris RP, Helfand M, Woolf SH, *et al.* Current methods of the US preventive services task force: a review of the process. *Am J Prev Med* 2001;20:21–35.
- 8 Benzon HT, Joshi GP, Gan TJ, *et al.* Development, reporting, and evaluation of clinical practice guidelines. *Anesth Analg* 2019;129:1771–7.
- 9 Sinha IP, Smyth RL, Williamson PR. Using the Delphi technique to determine which outcomes to measure in clinical trials: recommendations for the future based on a systematic review of existing studies. *PLoS Med* 2011;8:e1000393.
- 10 Hughey S, Schafer J, Cole J, *et al.* Ultrasound versus fluoroscopy for stellate ganglion block: a cadaveric study. *Pain Med* 2021;22:2307–10.
- 11 Santosh D, Lakhtakia S, Gupta R, *et al.* Clinical trial: a randomized trial comparing fluoroscopy guided percutaneous technique vs. endoscopic ultrasound guided technique of celiac plexus block for treatment of pain in chronic pancreatitis. *Aliment Pharmacol Ther* 2009;29:979–84.
- 12 Blanchard J, Ramamurthy S, Hoffman J. Celiac plexus block with steroids for chronic pancreatitis. *Reg Anesth* 1988;13:84.
- 13 Busch EH, Atchison SR. Steroid celiac plexus block for chronic pancreatitis: results in 16 cases. *J Clin Anesth* 1989;1:431–3.
- 14 Levy MJ, Topazian MD, Wiersma MJ, *et al.* Initial evaluation of the efficacy and safety of endoscopic ultrasound-guided direct ganglia neurolysis and block. *Am J Gastroenterol* 2008;103:98–103.
- 15 Sagir O, Demir HF, Ugun F, *et al.* Retrospective evaluation of pain in patients with coccydynia who underwent Impar ganglion block. *BMC Anesthesiol* 2020;20:110.
- 16 Sencan S, Edipoglu IS, Ulku Demir FG, *et al.* Are steroids required in the treatment of ganglion Impar blockade in chronic coccydynia? A prospective double-blinded clinical trial. *Korean J Pain* 2019;32:301–6.
- 17 Spiegel MA, Hingula L, Chen GH, *et al.* The use of L2 and L3 lumbar sympathetic blockade for cancer-related pain, an experience and recommendation in the oncologic population. *Pain Med* 2020;21:176–84.
- 18 Amr DrYM. Effect of early Stellate ganglion blockade for facial pain from acute herpes zoster and incidence of postherpetic neuralgia. *Pain Physician* 2012;6;15:E467–74.
- 19 Benzon HT, Linde HW, Hawes DD, *et al.* Stellate ganglion block using physiologic saline solution. *Anesthesiology* 1980;52:511.
- 20 Stevens T, Costanzo A, Lopez R, *et al.* Adding triamcinolone to endoscopic ultrasound-guided celiac plexus blockade does not reduce pain in patients with chronic pancreatitis. *Clin Gastroenterol Hepatol* 2012;10:186–91.
- 21 Rocha R de O, Teixeira MJ, Yeng LT, *et al.* Thoracic sympathetic block for the treatment of complex regional pain syndrome type I: a double-blind randomized controlled study. *Pain* 2014;155:2274–81.
- 22 Makkar JK. Effects of Stellate ganglion block on breast cancer-related lymphedema: comparison of various Injectates. *Pain Phys* 2015;18:1:93–9.
- 23 O'Toole T, Schmulewitz N. Complication rates of EUS-guided celiac plexus blockade and neurolysis: results of a large case series. *Endoscopy* 2009;41:593–7.
- 24 Stein B, Gardner Ti, Levenick J, *et al.* Retroperitoneal abscess following EUS-guided celiac plexus block. *Am J Gastroenterol* 2014;109:S449–50.
- 25 Olson DC, Lewis JJ. Steroid-induced psychosis after EUS-guided celiac plexus blockade. *ACG Case Rep J* 2017;4:e11.
- 26 Gupta N, Garg R, Saini S, *et al.* An unusual complication after ganglion Impar block for chronic cancer pain management. *AANA J* 2017;85:424–6.
- 27 Kuek DKC, Chung SL, Zishan US, *et al.* Conus infarction after non-guided transcoccygeal ganglion Impar block using particulate steroid for chronic coccydynia. *Spinal Cord Ser Cases* 2019;5:92.
- 28 Lo J, Vallée JN, Spelle L, *et al.* Unusual origin of the artery of Adamkiewicz from the fourth lumbar artery. *Neuroradiology* 2002;44:153–7.
- 29 Namba K. Vascular anatomy of the cauda equina and its implication on the vascular lesions in the caudal spinal structure. *Neurol Med Chir(Tokyo)* 2016;56:310–6.
- 30 Cesmebasi A, Muhleman MA, Hulsberg P, *et al.* Occipital neuralgia: anatomic considerations. *Clinical Anatomy* 2015;28:101–8.
- 31 van Suijlekom H, Van Zundert J, Narouze S, *et al.* 6. Cervicogenic headache. *Pain Practice* 2010;10:124–30.
- 32 Blumenfeld A, Ashkenazi A, Napchan U, *et al.* Expert consensus recommendations for the performance of peripheral nerve blocks for headaches—a narrative review. *Headache* 2013;53:437–46.
- 33 Ashkenazi A, Blumenfeld A, Napchan U, *et al.* Peripheral nerve blocks and trigger point injections in headache management - a systematic review and suggestions for future research. *Headache* 2010;50:943–52.
- 34 Ward JB. Greater occipital nerve block. *Semin Neurol* 2003;23:059–62.
- 35 Levin M. Nerve blocks in the treatment of headache. *Neurotherapeutics* 2010;7:197–203.
- 36 Loukas M, El-Sedfy A, Tubbs RS, *et al.* Identification of greater occipital nerve landmarks for the treatment of occipital neuralgia. *Folia Morphol (Warsz)* 2006;65:337–42.
- 37 Natsis K, Baraliakos X, Appell HJ, *et al.* The course of the greater occipital nerve in the suboccipital region: a proposal for setting landmarks for local anesthesia in patients with occipital neuralgia. *Clin Anat* 2006;19:332–6.
- 38 Ashkenazi A, Matro R, Shaw JW, *et al.* Greater occipital nerve block using local anaesthetics alone or with triamcinolone for transformed migraine: a randomised comparative study. *J Neurol Neurosurg Psychiatry* 2008;79:415–7.
- 39 Ducic I, Moriarty M, Al-Attar A. Anatomical variations of the occipital nerves: implications for the treatment of chronic headaches. *Plast Reconstr Surg* 2009;123:859–63.
- 40 Song Z, Zhao S, Ma J, *et al.* Fluoroscopy-guided blockade of the greater occipital nerve in cadavers. A comparison of spread and nerve involvement for different Injectate volumes. *Pain Res Manag* 2020;2020:8925895.
- 41 Racz G, Noe C, Justiz R. Suboccipital compartment decompression. In: Raj P, ed. *Interventional Pain Management Image-Guided Procedures*. 2nd edn. Saunders, 2008: 103–6.
- 42 Lauretti GR, Corrêa SWRO, Mattos AL. Efficacy of the greater occipital nerve block for cervicogenic headache: comparing classical and subcompartmental techniques. *Pain Pract* 2015;15:654–61.
- 43 Flamer D, Alakkad H, Soneji N, *et al.* Comparison of two ultrasound-guided techniques for greater occipital nerve injections in chronic migraine: a double-blind, randomized, controlled trial. *Reg Anesth Pain Med* 2019;44:595–603.
- 44 Palamar D, Uluduz D, Saip S, *et al.* Ultrasound-guided greater occipital nerve block: an efficient technique in chronic refractory migraine without aura? *Pain Physician* 2015;2;18:153–62.
- 45 Naja ZM, El-Rajab M, Al-Tannir MA, *et al.* Occipital nerve blockade for cervicogenic headache: a double-blind randomized controlled clinical trial. *Pain Pract* 2006;6:89–95.
- 46 Shim JH, Ko SY, Bang MR, *et al.* Ultrasound-guided greater occipital nerve block for patients with occipital headache and short term follow up. *Korean J Anesthesiol* 2011;61:50–4.
- 47 Greher M, Moriggl B, Curatolo M, *et al.* Sonographic visualization and ultrasound-guided blockade of the greater occipital nerve: a comparison of two selective techniques confirmed by anatomical dissection. *Br J Anaesth* 2010;104:637–42.
- 48 Vanderhoek MD, Hoang HT, Goff B. Ultrasound-guided greater occipital nerve blocks and pulsed radiofrequency ablation for diagnosis and treatment of occipital neuralgia. *Anesth Pain Med* 2013;3:256–9.
- 49 Pingree MJ, Sole JS, O'Brien TG, *et al.* Clinical efficacy of an ultrasound-guided greater occipital nerve block at the level of C2. *Reg Anesth Pain Med* 2017;42:99–104.
- 50 Peng PWH, Narouze S. Ultrasound-guided interventional procedures in pain medicine: a review of anatomy, Sonoanatomy, and procedures: Part I: nonaxial structures. *Reg Anesth Pain Med* 2009;34:458–74.
- 51 Eichenberger U, Greher M, Kapral S, *et al.* Sonographic visualization and ultrasound-guided block of the third occipital nerve: prospective for a new method to diagnose C2-C3 Zygapophysial joint pain. *Anesthesiology* 2006;104:303–8.
- 52 Biondi DM. Cervicogenic headache: a review of diagnostic and treatment strategies. *J Am Osteopath Assoc* 2005;105:165–225.
- 53 Bigo A, Delrieu F, Boussier MG. Treatment of vascular pain of the face by methylprednisolone injection into the area of the greater occipital nerve: 16 cases. *Rev Neurol (Paris)* 1989;145:160–2.
- 54 Scattoni L, Di Stani F, Villani V, *et al.* Great occipital nerve blockade for cluster headache in the emergency department: case report. *J Headache Pain* 2006;7:98–100.
- 55 Baron EP, Tepper SJ, Mays M, *et al.* Acute treatment of basilar-type migraine with greater occipital nerve blockade. *Headache* 2010;50:1057–9.
- 56 Di Stani F, Piovesan EJ, Scattoni L, *et al.* Occipital neuroma triggered cluster headache responding to greater occipital nerve blockade. *Arq Neuro-Psiquiatr* 2008;66:74–6.
- 57 Tobin JA, Flitman SS. Occipital nerve blocks: effect of symptomatic medication: overuse and headache type on failure rate. *Headache* 2009;49:1479–85.
- 58 Young WB, Mateos V, Ashkenazi A. Occipital nerve block rapidly eliminates allodynia far from the site of headache: a case report. *Cephalalgia* 2004;24:906–7.
- 59 Rozen T. Cessation of hemiplegic migraine auras with greater occipital nerve blockade. *Headache* 2007;47:917–9.
- 60 Gantenbein AR, Lutz NJ, Riederer F, *et al.* Efficacy and safety of 121 injections of the greater occipital nerve in episodic and chronic cluster headache. *Cephalalgia* 2012;32:630–4.
- 61 Gawel MJ, Rothbart PJ. Occipital nerve block in the management of headache and cervical pain. *Cephalalgia* 1992;12:9–13.
- 62 Anthony M. Headache and the greater occipital nerve. *Clin Neurol Neurosurg* 1992;94:297–301.
- 63 Ertem DH, Yilmaz İ. Effects of repetitive greater occipital nerve blocks on cervicogenic headache. *Tnd* 2019;25:82–6.
- 64 Anthony M. Cervicogenic headache: prevalence and response to local steroid therapy. *Clin Exp Rheumatol* 2000;18:559–64.

- 65 Saadah HA, Taylor FB. Sustained headache syndrome associated with tender occipital nerve zones. *Headache* 1987;27:201–5.
- 66 Anthony M. Arrest of attacks of cluster headache by local steroid injection of the occipital nerve. In: *Migraine*. Basel: Karger, 1985: 169–73. Available: <https://karger.com/books/book/1705/chapter-abstract/5667318/Arrest-of-Attacks-of-Cluster-Headache-by-Local>
- 67 Peres MF, Stiles MA, Siow HC, et al. Greater occipital nerve blockade for cluster headache. *Cephalalgia* 2002;22:520–2.
- 68 Lambru G, Abu Bakar N, Stahlhut L, et al. Greater occipital nerve blocks in chronic cluster headache: a prospective open-label study. *Euro J Neurology* 2014;21:338–43.
- 69 Ashkenazi A, Young WB. The effects of greater occipital nerve block and trigger point injection on brush allodynia and pain in migraine. *Headache* 2005;45:350–4.
- 70 Weibelt S, Andress-Rothrock D, King W, et al. Suboccipital nerve blocks for suppression of chronic migraine: safety, efficacy, and predictors of outcome. *Headache* 2010;50:1041–4.
- 71 Shawagfeh M, Bani Melhem G, Khsawneh J. The effect of bilateral block of greater occipital nerve on chronic migraine. *JRMS* 2017;24:57–61.
- 72 Leinisch-Dahlke E, Jürgens T, Bogdahn U, et al. Greater occipital nerve block is ineffective in chronic tension type headache. *Cephalalgia* 2005;25:704–8.
- 73 Ambrosini A, Vandenheede M, Rossi P, et al. Suboccipital injection with a mixture of rapid- and long-acting steroids in cluster headache: a double-blind placebo-controlled study. *Pain* 2005;118:92–6.
- 74 Leroux E, Valade D, Taifas I, et al. Suboccipital steroid injections for transitional treatment of patients with more than two cluster headache attacks per day: a randomised, double-blind, placebo-controlled trial. *Lancet Neurol* 2011;10:891–7.
- 75 Dilli E, Halker R, Vargas B, et al. Occipital nerve block for the short-term preventive treatment of migraine: a randomized, double-blinded, placebo-controlled study. *Cephalalgia* 2015;35:959–68.
- 76 Kashipazha D, Nakhostin-Mortazavi A, Mohammadianinejad SE, et al. Preventive effect of greater occipital nerve block on severity and frequency of migraine headache. *Glob J Health Sci* 2014;6:209–13.
- 77 Khatir AA, Panahkhahi M, Nasiri AK, et al. Greater occipital nerve block by bupivacaine/methyl prednisolone vs. bupivacaine/normal saline in medication overuse headache. *Tehran Univ Med J* 2012;70.
- 78 Schetman D, Hambrick GW, Wilson CE. Cutaneous changes following local injection of triamcinolone. *Arch Dermatol* 1963;88:820.
- 79 Shields KG, Levy MJ, Goadsby PJ. Alopecia and cutaneous atrophy after greater occipital nerve infiltration with corticosteroid. *Neurology* 2004;63:2193–4.
- 80 Mutagi H, Doger A, Kapur S. Full-thickness local soft tissue atrophy following steroid injection to greater occipital nerve. *Pain Practice* 2011;11:582–3.
- 81 Goldman L, O'Hara H, Baskett J. A study of the local tissue reactions in man to cortisone and compound F.VI. histopathological studies of the local effect of compound F in normal and pathologic skin of man. *J Invest Dermatol* 1953;20:271–83.
- 82 Shumaker PR, Rao J, Goldman MP. Treatment of local, persistent cutaneous atrophy following corticosteroid injection with normal saline infiltration. *Dermatologic Surgery* 2005;31:1340–3.
- 83 Cardone DA, Tallia AF. Joint and soft tissue injection. *Am Fam Physician* 2002;66:283–8.
- 84 Fredman R, Tenenhaus M. Cushing's syndrome after Intralesional triamcinolone acetate: a systematic review of the literature and multinational survey. *Burns* 2013;39:549–57.
- 85 Lavin PJ, Workman R. Cushing syndrome induced by serial occipital nerve blocks containing corticosteroids. *Headache* 2001;41:902–4.
- 86 Spinner D, Kirschner JS. Accuracy of ultrasound-guided superficial trigeminal nerve blocks using methylene blue in cadavers. *Pain Med* 2012;13:1469–73.
- 87 Dimitriou V, Iatrou C, Malefaki A, et al. Blockade of branches of the ophthalmic nerve in the management of acute attack of migraine. *Middle East J Anaesthesiol* 2002;16:499–504.
- 88 Caputi CA, Firetto V. Therapeutic blockade of greater occipital and supraorbital nerves in migraine patients. *Headache* 1997;37:174–9.
- 89 Caminerio AB, Pareja JA. Supraorbital neuralgia: a clinical study. *Cephalalgia* 2001;21:216–23.
- 90 Mulero P, Guerrero AL, Pedraza M, et al. Non-traumatic supraorbital neuralgia: a clinical study of 13 cases. *Cephalalgia* 2012;32:1150–3.
- 91 Sjaastad O, Stolt-Nielsen A, Pareja JA, et al. On the clinical manifestations and a possible therapeutic approach. *Headache* 1999;39:204–12.
- 92 Aggarwal A, Suresh V, Gupta B, et al. Post-herpetic neuralgia: a systematic review of current interventional pain management strategies. *J Cutan Aesthet Surg* 2020;13:265.
- 93 Gress K, Charipova K, Kassem H, et al. A comprehensive review of slipping rib syndrome: treatment and management. *Psychopharmacol Bull* 2020;50:189–96.
- 94 Waldman SD, Feldstein GS, Donohoe CD, et al. The relief of body wall pain secondary to malignant hepatic metastases by Intercostal nerve block with bupivacaine and methylprednisolone. *J Pain Symptom Manage* 1988;3:39–43.
- 95 Laughlin RS MD. Spinal cord injury from fluoroscopically guided intercostal blocks with phenol. *Pain Physician* 2014;2;17:E219–24.
- 96 Kim HJ, Ahn HS, Lee JY, et al. Effects of applying nerve blocks to prevent postherpetic neuralgia in patients with acute herpes zoster: a systematic review and meta-analysis. *Korean J Pain* 2017;30:3–17.
- 97 Lin CS, Lin YC, Lao HC, et al. Interventional treatments for postherpetic neuralgia: a systematic review. *Pain Physician* 2019;3:209–28.
- 98 Ho A-H, Karmakar MK, Critchley LAH. Acute pain management of patients with multiple fractured ribs. *Curr Opin Crit Care* 2011;17:323–7.
- 99 Makharia MY, Amr YM, El-Bayoumy Y. Single paravertebral injection for acute thoracic herpes zoster: a randomized controlled trial. *Pain Pract* 2015;15:229–35.
- 100 Patnaik R, Chhabra A, Subramaniam R, et al. Comparison of paravertebral block by anatomic landmark technique to ultrasound-guided paravertebral block for breast surgery anesthesia: a randomized controlled trial. *Reg Anesth Pain Med* 2018;43:385–90.
- 101 Shankar H, Eastwood D. Retrospective comparison of ultrasound and fluoroscopic image guidance for intercostal steroid injections. *Pain Pract* 2010;10:312–7.
- 102 Gulati A, Shah R, Puttanniah V, et al. A retrospective review and treatment paradigm of interventional therapies for patients suffering from intractable thoracic chest wall pain in the oncologic population. *Pain Med* 2015;16:802–10.
- 103 Drager C, Benziger D, Gao F, et al. Prolonged intercostal nerve blockade in sheep using controlled-release of bupivacaine and dexamethasone from polymer microspheres. *Anesthesiology* 1998;89:969–79.
- 104 Makharia MY, Amr YM. Effect of repeated paravertebral injections with local anesthetics and steroids on prevention of post-herpetic neuralgia. *Pain Physician* 2020;6;23:565–72.
- 105 Ji G, Niu J, Shi Y, et al. The effectiveness of repetitive paravertebral injections with local anesthetics and steroids for the prevention of postherpetic neuralgia in patients with acute herpes zoster. *Anesth Analg* 2009;109:1651–5.
- 106 Rispoli L, Rakesh N, Shah R, et al. Interventional pain treatments in the management of oncologic patients with thoracic spinal tumor-related pain: a case series. *Pain Practice* 2019;19:866–74.
- 107 Majumder A, Fayeizadeh M, Neupane R, et al. Benefits of multimodal enhanced recovery pathway in patients undergoing open ventral hernia repair. *J Am Coll Surg* 2016;222:1106–15.
- 108 McDermott G, Korba E, Mata U, et al. Should we stop doing blind transversus abdominis plane blocks? *Br J Anaesth* 2012;108:499–502.
- 109 Sahoo RK, Nair AS. Ultrasound guided transversus abdominis plane block for anterior cutaneous nerve entrapment syndrome. *Korean J Pain* 2015;28:284–6.
- 110 Niraj G, Kamel Y. Ultrasound-guided subcostal TAP block with depot steroids in the management of chronic abdominal pain secondary to chronic pancreatitis: a three-year prospective audit in 54 patients. *Pain Med* 2020;21:118–24.
- 111 Abd-Elseyed A, Luo S, Falls C. Transversus abdominis plane block as a treatment modality for chronic abdominal pain. *Pain Physician* 2020;4;23:405–12.
- 112 Abd-Elseyed A, Malyuk D. Efficacy of transversus abdominis plane steroid injection for treating chronic abdominal pain. *Pain Pract* 2018;18:48–52.
- 113 Mol FMU, Jansen CH, Boelens OB, et al. Adding steroids to lidocaine in a therapeutic injection regimen for patients with abdominal pain due to anterior cutaneous nerve entrapment syndrome (ACNES): a single blinded randomized clinical trial. *Scand J Pain* 2018;18:505–12.
- 114 Eichenberger U, Greher M, Kirchmair L, et al. Ultrasound-guided blocks of the ilioinguinal and iliohypogastric nerve: accuracy of a selective new technique confirmed by anatomical dissection. *Br J Anaesth* 2006;97:238–43.
- 115 Trainor D, Moeschler S, Pingree M, et al. Landmark-based versus ultrasound-guided ilioinguinal/iliohypogastric nerve blocks in the treatment of chronic postherniorrhaphy groin pain: a retrospective study. *J Pain Res* 2015;8:767–70.
- 116 Thomassen I, van Suijlekom JA, van de Gaag A, et al. Ultrasound-guided ilioinguinal/iliohypogastric nerve blocks for chronic pain after inguinal hernia repair. *Hernia* 2013;17:329–32.
- 117 Khan JS, Rai A, Sundara Rajan R, et al. A scoping review of perineural steroids for the treatment of chronic postoperative inguinal pain. *Hernia* 2016;20:367–76.
- 118 Yang C, Xu H, Wang R, et al. The management of hemiplegic shoulder pain in stroke subjects undergoing pulsed radiofrequency treatment of the suprascapular and axillary nerves: a pilot study. *Ann Palliat Med* 2020;9:3357–65.
- 119 Sir E, Eksert S. Ultrasound-guided pulsed radiofrequency neuromodulation of the suprascapular nerve in partial rotator cuff tears. *Turk J Med Sci* 2019;49:1524–8.
- 120 Saglam G, Alisar DC. A comparison of the effectiveness of ultrasound-guided versus landmark-guided suprascapular nerve block in chronic shoulder pain: a prospective randomized study. *Pain Physician* 2020;23:581–8.
- 121 Sá Malheiro N, Afonso NR, Pereira D, et al. Efficacy of ultrasound guided suprascapular block in patients with chronic shoulder pain: retrospective observational study. *Braz J Anesthesiol (English Edition)* 2020;70:15–21.
- 122 Wagle S, Glazebrook K, Moynagh M, et al. Role of ultrasound-guided perineural injection of the posterior antebrachial cutaneous nerve for diagnosis and potential treatment of chronic lateral elbow pain. *Skeletal Radiol* 2021;50:425–30.
- 123 Rose NE, Forman SK, Dellon AL. Denervation of the lateral humeral epicondyle for treatment of chronic lateral epicondylitis. *J Hand Surg Am* 2013;38:344–9.
- 124 Gibbons JJ, Wilson PR, Lamer TJ, et al. Interscalene blocks for chronic upper extremity pain. *Clin J Pain* 1992;8:264–9.

- 125 Fewtrell MS, Sapsford DJ, Herrick MJ, *et al.* Continuous axillary nerve block for chronic pain. *Arch Dis Child* 1994;70:54–5.
- 126 dos Santos Fernandes H, Lima Filho PEP, Gouvêa AL, *et al.* Continuous peripheral nerve block for upper limb ischemic pain: a case report. *Braz J Anesthesiol (English Edition)* 2021;71:451–3.
- 127 Bak TS, Bøgevig S, Christensen AP, *et al.* Phrenic nerve block on severe post-hepatectomy shoulder pain: a randomized, double-blind, placebo-controlled, pilot study. *Acta Anaesthesiol Scand* 2021;65:1320–8.
- 128 Okur SC, Ozyemisci-Taskiran O, Pekindogan Y, *et al.* Ultrasound-guided block of the suprascapular nerve in breast cancer survivors with limited shoulder motion – case series. *Pain Physician* 2017;20:E233–9.
- 129 Canders CP, Krishna PK, Moheimani RS, *et al.* Management of an acute exacerbation of chronic neuropathic pain in the emergency department: a case to support ultrasound-guided forearm nerve blocks. *J Emerg Med* 2018;55:e147–51.
- 130 Fuzier R, Izard P, Daboussi A, *et al.* A case report of sustained resolution of cancer pain by continuous perineural infusion of local anaesthetic. *Eur J Pain* 2019;23:31–4.
- 131 Wilson JK, Sevier TL. A review of treatment for carpal tunnel syndrome. *Disabil Rehabil* 2003;25:113–9.
- 132 Marshall S, Tardif G, Ashworth N. Local corticosteroid injection for carpal tunnel syndrome. *Cochrane Database Syst Rev* 2007;2:CD001554.
- 133 Wu Y-T, Wu C-H, Lin J-A, *et al.* Efficacy of 5% dextrose water injection for peripheral entrapment neuropathy: a narrative review. *Int J Mol Sci* 2021;22:12358.
- 134 Kamel SR, Sadek HA, Hamed A, *et al.* Ultrasound-guided insulin injection for carpal tunnel syndrome in type 2 diabetes mellitus patients. *Clin Rheumatol* 2019;38:2933–40.
- 135 Karaahmet ÖZ, Gürçay E, Kara M, *et al.* Comparing the effectiveness of ultrasound-guided versus blind steroid injection in the treatment of severe carpal tunnel syndrome. *Türk J Med Sci* 2017;47:1785–90.
- 136 Lee JY, Park Y, Park KD, *et al.* Effectiveness of ultrasound-guided carpal tunnel injection using in-plane Ulnar approach: a prospective, randomized, single-blinded study. *Medicine (Baltimore)* 2014;93:e350.
- 137 Chen PC, Wang LY, Pong YP, *et al.* Effectiveness of ultrasound-guided vs direct approach corticosteroid injections for carpal tunnel syndrome: a double-blind randomized controlled trial. *J Rehabil Med* 2018;50:200–8.
- 138 Roh YH, Hwangbo K, Gong HS, *et al.* Comparison of ultrasound-guided versus landmark-based corticosteroid injection for carpal tunnel syndrome: a prospective randomized trial. *J Hand Surg Am* 2019;44:304–10.
- 139 Salinas FV. Evidence basis for ultrasound guidance for lower-extremity peripheral nerve block: update 2016. *Reg Anesth Pain Med* 2016;41:261–74.
- 140 Tran DQ, Salinas FV, Benzon HT, *et al.* Lower extremity regional anesthesia: essentials of our current understanding. *Reg Anesth Pain Med* 2019;44:143–80.
- 141 Mishra P, Tandon S, Nath A. Extended pulsed radiofrequency as a part of multimodal pain management in a refractory case of Bernhardt-Roth syndrome. *BMJ Case Rep* 2020;13:e237864.
- 142 Fowler IM, Tucker AA, Mendez RJ. Treatment of meralgia paresthetica with ultrasound-guided pulsed radiofrequency ablation of the lateral femoral cutaneous nerve. *Pain Pract* 2012;12:394–8.
- 143 Öztürk G MD. Conservative treatment versus ultrasound-guided injection in the management of meralgia paresthetica: a randomized controlled trial. *Pain Phys* 2020;3:23:253–64.
- 144 Tagliafico A, Serafini G, Lacelli F, *et al.* Ultrasound-guided treatment of meralgia paresthetica (lateral femoral cutaneous neuropathy): technical description and results of treatment in 20 consecutive patients. *J Ultrasound Med* 2011;30:1341–6.
- 145 Tumber PS, Bhatia A, Chan VW. Ultrasound-guided lateral femoral cutaneous nerve block for meralgia paresthetica. *Anesth & Analg* 2008;106:1021–2.
- 146 Candido KD MD. Successful treatment of meralgia paresthetica with pulsed radiofrequency of the lateral femoral cutaneous nerve. *Pain Physician* 2009;5:12:881–5.
- 147 Pouliquen U, Riant T, Robert R, *et al.* La Névralgie Clunéale Inférieure par Conflit au Niveau de L'ischion : identification D'Une Entité Clinique À Partir D'Une Série de blocs Anesthésiques Chez 72 patients. *Progrès En Urologie* 2012;22:1051–7.
- 148 Zeliha Karaahmet O, Gurçay E, Öztürk D, *et al.* A rare presentation of meralgia paraesthetica in limb girdle muscular dystrophy. *Scott Med J* 2018;63:25–7.
- 149 Labat JJ, Riant T, Lassaux A, *et al.* Adding corticosteroids to the pudendal nerve block for pudendal neuralgia: a randomised, double-blind, controlled trial. *BJOG* 2017;124:251–60.
- 150 Franco H, Pagliaro T, Sparti C, *et al.* Comparing clinical examination and radiological evaluation in the preoperative diagnosis and location of symptomatic Interdigital (Morton's) neuroma. *J Foot Ankle Surg* 2023;62:883–7.
- 151 Wu KK. Morton's interdigital neuroma: a clinical review of its etiology, treatment, and results. *J Foot Ankle Surg* 1996;35:112–9.
- 152 Ruiz Santiago F, Prados Olleta N, Tomás Muñoz P, *et al.* Short term comparison between blind and ultrasound guided injection in Morton neuroma. *Eur Radiol* 2019;29:620–7.
- 153 Thomson L, Aujla RS, Divall P, *et al.* Non-surgical treatments for Morton's neuroma: a systematic review. *Foot Ankle Surg* 2020;26:736–43.
- 154 Saygi B, Yildirim Y, Saygi EK, *et al.* Morton neuroma: comparative results of two conservative methods. *Foot Ankle Int* 2005;26:556–9.
- 155 Markovic M, Crichton K, Read JW, *et al.* Effectiveness of ultrasound-guided corticosteroid injection in the treatment of Morton's neuroma. *Foot Ankle Int* 2008;29:483–7.
- 156 Thomson CE, Beggs I, Martin DJ, *et al.* Methylprednisolone injections for the treatment of Morton neuroma: a patient-blinded randomized trial. *J Bone Joint Surg Am* 2013;95:790–8.
- 157 Alvarez DJ, Rockwell PG. Trigger points: diagnosis and management. *Am Fam Physician* 2002;65:653–60.
- 158 Lavelle ED, Lavelle W, Smith HS. Myofascial trigger points. *Med Clin North Am* 2007;91:229–39.
- 159 Simons DG. Review of enigmatic MTrPs as a common cause of enigmatic musculoskeletal pain and dysfunction. *J Electromyogr Kinesiol* 2004;14:95–107.
- 160 Shah JP, Danoff JV, Desai MJ, *et al.* Biochemicals associated with pain and inflammation are elevated in sites near to and remote from active myofascial trigger points. *Arch Phys Med Rehabil* 2008;89:16–23.
- 161 Shah JP, Phillips TM, Danoff JV, *et al.* An in vivo microanalytical technique for measuring the local biochemical milieu of human skeletal muscle. *J Appl Physiol* (1985) 2005;99:1977–84.
- 162 Shah JP, Thaker N, Heimur J, *et al.* Myofascial trigger points then and now: a historical and scientific perspective. *PM R* 2015;7:746–61.
- 163 Sikdar S, Shah JP, Gebreab T, *et al.* Novel applications of ultrasound technology to visualize and characterize myofascial trigger points and surrounding soft tissue. *Arch Phys Med Rehabil* 2009;90:1829–38.
- 164 Turo D, Otto P, Hossain M, *et al.* Novel use of ultrasound elastography to quantify muscle tissue changes after dry needling of myofascial trigger points in patients with chronic myofascial pain. *J Ultrasound Med* 2015;34:2149–61.
- 165 Kumbhare D, Singh D, Rathbone H A, *et al.* Ultrasound-guided Interventional procedures: myofascial trigger points with structured literature review. *Reg Anesth Pain Med* 2017;42:407–12.
- 166 Shankar H, Reddy S. Two- and three-dimensional ultrasound imaging to facilitate detection and targeting of taut bands in myofascial pain syndrome. *Pain Med* 2012;13:971–5.
- 167 Thomas K, Shankar H. Targeting myofascial taut bands by ultrasound. *Curr Pain Headache Rep* 2013;17:349.
- 168 Lewit K. The needle effect in the relief of myofascial pain. *Pain* 1979;6:83–90.
- 169 Dunning J, Butts R, Mourad F, *et al.* Dry needling: a literature review with implications for clinical practice guidelines. *Phys Ther Rev* 2014;19:252–65.
- 170 Navarro-Santana MJ, Sanchez-Infante J, Gómez-Chiguano GF, *et al.* Dry needling versus trigger point injection for neck pain symptoms associated with myofascial trigger points: a systematic review and meta-analysis. *Pain Med* 2022;23:515–25.
- 171 Hammi C, Schroeder JD, Yeung B. Trigger point injection. StatPearls; 2021.
- 172 Botwin KP, Sharma K, Saliba R, *et al.* Ultrasound-guided trigger point injections in the cervicthoracic musculature: a new and unreported technique. *Pain Physician* 2008;11:885–9.
- 173 Wong CSM, Wong SHS. A new look at trigger point injections. *Anesthesiol Res Pract* 2012;2012:492452.
- 174 Domingo T, Blasi J, Casals M, *et al.* Is interfascial block with ultrasound-guided puncture useful in treatment of myofascial pain of the trapezius muscle. *Clin J Pain* 2011;27:297–303.
- 175 Rha D, Shin JC, Kim Y-K, *et al.* Detecting local twitch responses of Myofascial trigger points in the lower-back muscles using ultrasonography. *Arch Phys Med Rehabil* 2011;92:1576–80.
- 176 Kang JJ, Kim J, Park S, *et al.* Feasibility of ultrasound-guided trigger point injection in patients with myofascial pain syndrome. *Healthcare (Basel)* 2019;7:118.
- 177 Ricci V, Özçakar L. Ultrasound imaging of the upper trapezius muscle for safer myofascial trigger point injections: a case report. *Phys Sportsmed* 2019;47:247–8.
- 178 Vargas-Schaffer G, Nowakowsky M, Egtesadi M, *et al.* Ultrasound-guided trigger point injection for serratus anterior muscle pain syndrome: description of technique and case series. *AA Case Rep* 2015;5:99–102.
- 179 De Mynck M, Parlevliet T, De Cock K, *et al.* Musculoskeletal ultrasound for interventional physiatry. *Eur J Phys Rehabil Med* 2012;48:675–87.
- 180 Finnoff JT, Costouros JG, Kennedy DJ. Is ultrasound guidance needed for shoulder injections. *PM&R* 2015;7:435–42.
- 181 Daniels EW, Cole D, Jacobs B, *et al.* Existing evidence on ultrasound-guided injections in sports medicine. *Orthop J Sports Med* 2018;6:2325967118756576.
- 182 Bubnov RV, Wang J. Clinical comparative study for ultrasound-guided trigger-point needling for myofascial pain. *Medical Acupuncture* 2013;25:437–43.
- 183 Farrow RA, Newberry M, Zitek T, *et al.* Ultrasound-guided trigger point injections for the treatment of neck and back pain in the emergency department: a randomized trial. *J Med Ultrasound* 2023;42:1023–32.
- 184 Kocak AO, Ahiskalioglu A, Sengun E, *et al.* Comparison of intravenous NSAIDs and trigger point injection for low back pain in ED: a prospective randomized study. *Am J Emerg Med* 2019;37:1927–31.
- 185 Zink W, Graf BM. Local anesthetic myotoxicity. *Reg Anesth Pain Med* 2004;29:333–40.



- 186 Hussain N, McCartney CJL, Neal JM, *et al.* Local anaesthetic-induced myotoxicity in regional anaesthesia: a systematic review and empirical analysis. *Br J Anaesth* 2018;121:822–41.
- 187 Zhang K, Li M, Yao W, *et al.* Cytotoxicity of local anesthetics on bone, joint, and muscle tissues: a narrative review of the current literature. *J Pain Res* 2023;16:611–21.
- 188 Krishnan SK, Benzon HT, Siddiqui T, *et al.* Pain on Intramuscular injection of bupivacaine, ropivacaine, with and without dexamethasone. *Reg Anesth Pain Med* 2000;25:615–9.
- 189 Garvey TA, Marks MR, Wiesel SW. A prospective, randomized, double-blind evaluation of trigger-point injection therapy for low-back pain. *Spine* 1989;14:962–4.
- 190 Venâncio R de A, Alencar FGPI, Zamperini C. Different substances and dry-needling injections in patients with myofascial pain and headaches. *Cranio* 2008;26:96–103.
- 191 Misirlioglu TO, Akgun K, Palamar D, *et al.* Piriformis syndrome: comparison of the effectiveness of local anesthetic and corticosteroid injections: a double-blinded, randomized controlled study. *Pain Physician* 2015;18:163–71.
- 192 Brennan KL, Allen BC, Maldonado YM. Dry needling versus cortisone injection in the treatment of greater trochanteric pain syndrome: a noninferiority randomized clinical trial. *J Orthop Sports Phys Ther* 2017;47:232–9.
- 193 Moya Esteban BM, Solano Calvo JA, Torres Morcillo C, *et al.* Retrospective case review of combined local mepivacaine and steroid injections into vaginal trigger points for the management of moderate-to-severe perineal pain after childbirth. *Arch Gynecol Obstet* 2019;299:501–5.
- 194 Scott NA, Guo B, Barton PM, *et al.* Trigger point injections for chronic non-malignant musculoskeletal pain: a systematic review. *Pain Med* 2009;10:54–69.
- 195 Lavelle ED, Lavelle W, Smith HS. Myofascial trigger points. *Anesthesiol Clin* 2007;25:841–51.
- 196 Malanga GA, Cruz Colon EJ. Myofascial low back pain: a review. *Phys Med Rehabil Clin N Am* 2010;21:711–24.
- 197 Robbins MS, Kuruvilla D, Blumenfeld A, *et al.* Trigger point injections for headache disorders: expert consensus methodology and narrative review. *Headache* 2014;54:1441–59.
- 198 Kim SG, Shim KS, Lee DW, *et al.* Intramuscular Hematoma with motor weakness after trigger point injection: a case report. *Medicine* 2017;96:e8135.
- 199 Kim JB, Chang MC. Spinal cord injury by direct damage during trigger point injection: a case report. *J Int Med Res* 2021;49:3000605211012367.
- 200 Ahiskalioglu EO, Alici HA, Dostbil A, *et al.* Pneumothorax after trigger point injection: a case report and review of literature. *J Back Musculoskelet Rehabil* 2016;29:895–7.
- 201 Sangondimath G, Varma Kalidindi KK, Pandrakula P, *et al.* An unusual complication of quadruparesis after trigger point injection: a case report. *Pain* 2021;162:711–3.
- 202 Soriano PK, Bhattarai M, Vogler CN, *et al.* A case of trigger-point injection-induced hypokalemic paralysis. *Am J Case Rep* 2017;18:454–7.
- 203 Salamone FJ, Kanamalla K, Songmen S, *et al.* Bilateral supraclavicular abscesses following trigger point injections. *Radiol Case Rep* 2021;16:2630–3.
- 204 Pace MM, Sharma B, Anderson-Dam J, *et al.* Ultrasound-guided thoracic paravertebral blockade: a retrospective study of the incidence of complications. *Anesth Analg* 2016;122:1186–91.
- 205 Rhim HC, Cha JH, Cha J, *et al.* Sonography-guided trigger point injections in abdominal myofascial pain syndrome. *Medicine (Baltimore)* 2020;99:e23408.
- 206 Benzon HT, Katz JA, Benzon HA, *et al.* Piriformis syndrome: anatomic considerations, a new injection technique, and a review of the literature. *Anesthesiology* 2003;98:1442–8.
- 207 Brouwers MC, Kerkvliet K, Spithoff K, *et al.* The AGREE reporting checklist: a tool to improve reporting of clinical practice guidelines. *BMJ* 2016;352:i1152.
- 208 AGREE Next Steps Consortium. The AGREE II instrument [Electronic version]. 2017. Available: <http://www.agreetrust.org> [Accessed 25 Apr 2019].
- 209 Davidson KW, Barry MJ, Mangione CM, *et al.* Screening for colorectal cancer: US preventive services task force recommendation statement. *JAMA* May 2021;325:1965–77.